

Interactions between the gingiva and the margin of restorations

Allan Padbury, Jr, Robert Eber
and Hom-Lay Wang

Department of Periodontics/Prevention/
Geriatrics, School of Dentistry, University of
Michigan, Ann Arbor, MI, USA

Padbury Jr A, Eber R, Wang H-L. Interactions between the gingiva and the margin of restorations. *J Clin Periodontol* 2003; 30: 379–385. © Blackwell Munksgaard, 2003.

Abstract

An adequate understanding of the relationship between periodontal tissues and restorative dentistry is paramount to ensure adequate form, function, esthetics, and comfort of the dentition. While most clinicians are aware of this important relationship, uncertainty remains regarding specific concepts such as the biologic width and indications and applications for surgical crown lengthening. This review discusses the concept of the biologic width and its relationship to periodontal health and restorative dentistry. The importance of restorative margin location, materials, and contours related to periodontal health is also addressed. The rationale and indications for surgical crown lengthening are elaborated. Particular surgical principles of crown lengthening are examined in detail.

Key words: restorations; crown margins; biological width; periodontal and gingival health

Accepted for publication 27 May 2002

Periodontal tissues form the foundation for proper esthetics, function, and comfort of the dentition. All prosthetic and restorative therapies generally require a healthy periodontium as a prerequisite for successful outcome. The interplay between periodontics and restorative dentistry is present at many fronts, including location of restorative margins, crown contours, and response of the gingival tissues to restorative preparations. The purpose of this review paper is to summarize both past and present literature regarding basic concepts of periodontal–restorative interactions, particularly with regard to interactions at the gingival margin, including the dentogingival attachment and the impact of restorations, which encroach upon these tissues.

Biologic Width

The term biologic width is familiar to most clinicians, yet there still exists confusion regarding its meaning and relevance to clinical procedures. The biologic width is defined as the dimension of the soft tissue, which is attached to the portion of the tooth coronal to the crest of the alveolar bone. This term was based on the work of Gargiulo et al. (1961), who described the dimensions

and relationship of the dentogingival junction in humans. Measurements made from the dentogingival components of 287 individual teeth from 30 autopsy specimens established that there is a definite proportional relationship between the alveolar crest, the connective tissue attachment, the epithelial attachment, and the sulcus depth. Gargiulo et al. (1961) reported the following mean dimensions: a sulcus depth of 0.69 mm, an epithelial attachment of 0.97 mm, and a connective tissue attachment of 1.07 mm. Based on this work, the biologic width is commonly stated to be 2.04 mm, which represents the sum of the epithelial and connective tissue measurements. One must realize however that significant variations of dimensions were observed, particularly the epithelial attachment, which ranged from 1.0 to 9.0 mm. The connective tissue attachment, on the other hand, was relatively constant. Recently, similar biologic width dimensions were also reported (Vacek et al. 1994). Evaluating 171 cadaver tooth surfaces, they observed mean measurements of 1.34 mm for sulcus depth, 1.14 for epithelial attachment, and 0.77 mm for connective tissue attachment. This group also found that the connective tissue attachment was the most consistent measurement (Fig. 1).

There is general agreement that placing restorative margins within the biologic width frequently leads to gingival inflammation, clinical attachment loss, and bone loss. This is thought to be due to the destructive inflammatory response to microbial plaque located at deeply placed restorative margins. Clinically, these changes are manifested as deepened periodontal pockets or gingival recession. These changes have been substantiated by studies that have assessed the histological and clinical responses of periodontal tissues to restorative margins placed within the biologic width. Newcomb (1974) analyzed 66 anterior crowns with subgingival margins of varying depths and compared them to uncrowned contralateral controls. The results showed that the nearer a subgingival crown margin was to the epithelial attachment (hence nearer the biologic width), the more likely that severe gingival inflammation occurred. Parma-Benfenati et al. (1986) observed approximately 5 mm of osseous resorption when restorative margins were placed at the alveolar crest in beagle dogs. Minimal resorption was observed where restorations were placed 4 mm coronal to the alveolar crest. Bone resorption was particularly severe in areas with thin cortical bone

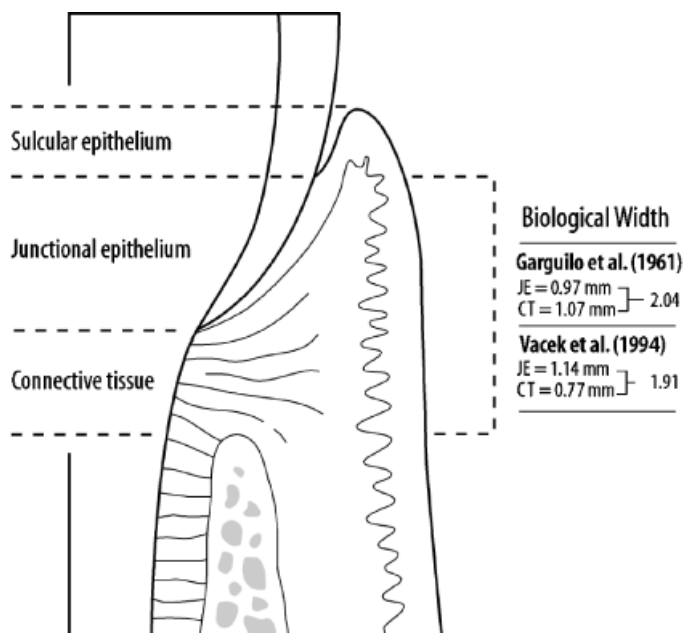


Fig. 1. Biologic width.

and interdental septa. Tal et al. (1989) further demonstrated that biologic width violation results in loss of periodontal support. Class V cavities were prepared in canine teeth of 43 beagle dogs so that the apical border rested on the alveolar crest. Control teeth had Class V notches placed at the cemento-enamel junction. All cavities were restored with amalgam, and 1 year following surgery, gingival recession and bone loss were significantly greater at test sites compared to control teeth (3.16 and 1.17 mm versus 0.5 and 0.15 mm, respectively). Recently, Gunay et al. (2000) demonstrated that restorative margin placement within the biologic width was detrimental to periodontal health. In a 2-year study, they evaluated 116 prepared teeth compared to 82 unrestored teeth in 41 patients. Papillary bleeding score and probing depths increased at sites where the restorative margin was <1 mm from the alveolar crest.

Encroachment of the biologic width becomes of particular concern when considering the restoration of a tooth that has fractured or been destroyed by caries near the alveolar crest level. Also, esthetic demands often require "burying" of restorative margins subgingivally, which can lead to violation of this space. Various authors have recommended minimal distances restorative

margins must be from the bone crest to avoid deleterious effects. Ingber et al. (1977) suggested that a minimum of 3 mm was required from the restorative margin to the alveolar crest to permit adequate healing and restoration of the tooth. Maynard & Wilson (1979) divided the periodontium into three dimensions: *superficial physiologic*, *crevicular physiologic*, and *subcrevicular physiologic*. The superficial physiologic dimension represents the free and attached gingiva surrounding the tooth, while the crevicular physiologic dimension represents the gingival crevice – extending from the free gingival margin to the junctional epithelium. The subcrevicular physiologic space is analogous to the biologic width described by Gargiulo et al. (1961), consisting of the junctional epithelium and connective tissue attachment. Maynard & Wilson claimed that all three of these dimensions affect restorative treatment decisions and the clinician should 'conceptualize' all three areas and the interplay between them and restorative margins. In particular, the authors claimed that margin placement into the subcrevicular physiologic space should be avoided to prevent the placement of 'permanent calculus' beyond the crevice. Nevins & Skurow (1984) stated that when subgingival margins are indicated, the restorative dentist must

not disrupt the junctional epithelium or connective tissue apparatus during preparation and impression taking. The authors recommended limiting subgingival margin extension to 0.5–1.0 mm because it is impossible for the clinician to detect where the sulcular epithelium ends and the junctional epithelium begins. They also emphasized allowing a minimum 3.0 mm distance from the alveolar crest to the crown margin. Block (1987) also claimed that the biologic width was difficult for clinicians to visualize and suggested the free gingival margin as the reference point for measurements for margin placement. Block stated that when restorative margins end at or near the alveolar crest level, surgical crown-lengthening procedures are necessary.

It is important to note that recommendations regarding placement of restorations in relation to the biologic width are based on opinion articles. They have evolved due to clinical experiences and interpretations of various experimental studies. Nonetheless, it appears that a minimum of 3.0 mm of space between restorative margins and alveolar bone is a dimension that is prudent to adhere to in restorative treatment planning.

Restorative Margin Location

Not only do restorative margins placed subgingivally risk invading the attachment apparatus, but also unwanted tissue effects appear to result merely due to their subgingival location, regardless of depth of sulcus penetration. Orkin et al. (1987) demonstrated that subgingival restorations had a greater chance of bleeding and exhibiting gingival recession than supragingival restorations. Silness (1980) evaluated the periodontal condition of the lingual surfaces of 385 fixed partial denture abutment teeth. He found that a supra-gingival position of the crown margin was the most favorable, whereas margins below the gingival margin significantly compromised gingival health. Renggli & Regolati (1972) demonstrated that gingivitis and plaque accumulation were more pronounced in interdental areas with well-adapted subgingival amalgam fillings compared to sound tooth structure. Waerhaug (1978) stated that subgingival restorations are plaque-retentive areas that are inaccessible to scaling instruments. These retentive areas continue to accumulate

plaque even in the presence of adequate supragingival plaque control.

In a cross-sectional study of 134 periodontitis patients, Wang et al. (1993) demonstrated that posterior teeth with crowns or proximal restorations were associated with more furcation involvement and greater attachment loss than teeth without proximal restorations. Stetler & Bissada (1987) evaluated the effects of width of keratinized gingiva and subgingival restorations on periodontal health. Teeth with subgingival restorations and narrow zones of keratinized gingiva showed significantly higher gingival index scores than teeth with submarginal restorations with wide zones of keratinized gingiva. Thus, clinicians should consider gingival augmentation for teeth with minimal keratinized gingiva before placing subgingival restorations.

Waerhaug (1980) demonstrated gingivitis and attachment loss associated with submarginal restorations in monkeys and dogs. Clinical and histological observations of human teeth by Dragoos & Williams (1981, 1982) demonstrated compromised healing associated with gingival bevel crown margins compared to shoulder preparations. Flores-de-Jacoby et al. (1989) studied the effects of crown margin location on periodontal health and bacterial morphotypes in humans 6–8 weeks and 1 year post-insertion. Subgingival margins demonstrated increased plaque, gingival index scores, and probing depths. Furthermore, more spirochetes, fusiforms, rods, and filamentous bacteria were found to be associated with subgingival margins.

The location of restorative margins is determined by many factors, including esthetics, retentive factors, susceptibility to root caries, and degree of gingival recession. While many clinicians place restorative margins subgingivally, the detrimental effects of margins below the free gingival margin is obviously well documented. While most periodontists would prefer restorative margins to remain coronal to the sulcus, it is understood that certain conditions necessitate placement of subgingival margins. These may include esthetic concerns, need for increased retention form, refinement of preexisting margins, root caries, cervical abrasion, and root sensitivity. However, if none of these factors is of concern, it appears prudent to place restorative margins supragingivally. It is also important for clinicians and patients to understand that

although crown margins may be placed subgingivally, it is highly likely that over time the margins will eventually be located supragingivally. Valderhaug & Birkeland (1976) evaluated 114 patients with 329 total crown restorations. Most of the crowns (59%) were located subgingivally at the beginning of the study period. After 5 years, only 32% of the crown margins remained below the gingival margin. They also demonstrated that greater mean attachment loss was associated with subgingival restorations compared to supragingival margins (1.2 versus 0.6 mm).

Restoration Overhangs

Overhanging dental restorations have long been viewed as a contributing factor to gingivitis and possible periodontal attachment loss. They pose a significant concern as their prevalence has been estimated at 25–76% for all restored surfaces (Brunsvold & Lane 1990). It is generally accepted that overhanging restorations contribute to gingival inflammation due to their retentive capacity for bacterial plaque. Gilmore & Sheiham (1971) illustrated interproximal radiographic bone loss adjacent to posterior teeth with overhanging restorations. Highfield & Powell (1978) demonstrated that overhang removal plus professional plaque control improved gingival indices and bone scores. Jeffcoat and Howell (1980) demonstrated a link to the severity of the overhang and the amount of periodontal destruction. Based upon radiographic evaluations of 100 teeth with overhangs and 100 without, they reported greater bone loss around teeth with large overhangs. The severity of bone loss was directly proportional to the severity of the overhang. Overhangs were designated as large if they occupied >51% of the interproximal space. Small and medium overhangs (<20% and 20–50% of the interproximal space, respectively) were not associated with bone loss. Lang et al. (1983) investigated the specific aspects of the local bacterial accumulation associated with overhanging restorations. Five gold MOD onlays with 1 mm overhangs were placed in mandibular molars of periodontally healthy dental students for 9–27 weeks. They were replaced in a cross-over design by onlays with clinically perfect margins. The placement of subgingival overhangs resulted in

changes in the associated microflora to that of one resembling the flora observed in adult chronic periodontitis. Increased proportions of Gram-negative anaerobic rods, in particular black pigmented *Bacteroides*, were observed. Chen et al. (1987) evaluated human extracted teeth with overhanging restorations compared to nonrestored teeth and reported greater attachment loss associated with overhang surfaces. Pack et al. (1990) assessed the prevalence of restoration overhangs and associated periodontal disease of 100 patients who had recently completed treatment. Sixty-two percent of all proximal restorations had overhanging margins, and periodontal disease was more severe when overhangs were present. When adjacent to neighboring teeth, overhanging margins also significantly affected the periodontal status of those teeth.

Thus, overhangs not only increase plaque mass but also increase the specific periodontal pathogens in the plaque. Most overhanging restorations can be recontoured without replacing the restoration, and this should be considered a standard component of nonsurgical treatment. A variety of devices have been suggested for overhang removal, most based on clinical opinions. One study demonstrated that a motor-driven diamond tip is faster for removing overhangs and led to smoother restorations compared to sonic scalers and curettes, respectively (Spinks et al. 1986).

Artificial Crown Contour

Regarding crown contour, conflicting reports exist regarding the proper contours necessary for maintaining gingival health. Some report that an artificial crown should follow the original anatomy of tooth contour to permit functional stimulation and to maintain gingival health. Others advise that crowns should be undercontoured for better periodontal health. Yuodelis et al. (1973) demonstrated that the greater the amount of facial and lingual bulge of an artificial crown, the more the plaque retained at the cervical margin. Ehrlich & Hochman (1980) evaluated differences in subgingival crown contours in four periodontally healthy patients and determined that factors other than variations in crown contour of ± 1 mm determined gingival response. In a

review of periodontal–prosthetic interactions, Becker & Kaldahl (1981) opined that buccal and lingual crown contours should be “flat”, not “fat”, usually <0.5 mm wider than the CEJ, and that furcation areas should be “fluted” or “barreled out” to accommodate oral hygiene in these areas.

Proximal Contact Relationships

Clinical impressions suggest loose or open proximal contacts to be contributing factors to periodontal pocket formation. Nonetheless, the literature proposes conflicting views on the subject. This may be due to different oral hygiene levels of the different study populations. Kopic & O’Leary (1978), for example, demonstrated no difference in periodontal breakdown at sites with deficient proximal contacts compared to satisfactory sites, provided adequate oral hygiene was maintained. Larato (1971) evaluated 121 dry adult human skulls and found that only 38 of 206 intrabony lesions (18%) were associated with factors able to cause food impaction. While the role of deficient interproximal integrity may be unclear, open contacts leading to food impaction are often uncomfortable to the patient, and it is still generally accepted that tight interproximal contacts are important for gingival health. Hancock et al. (1980) evaluated 40 naval recruits to determine the relationship of interdental contacts on periodontal status. Results revealed no significant relationship between contact type and gingival index or probing depth. However, a significant relationship was seen between food impaction and contact type (greater food impaction at sites with open or loose contacts), and between food impaction and probing depth. These findings help support the notion that food impaction contributes to periodontal disease.

Surgical Crown Lengthening

Crown-lengthening surgery is designed to increase clinical crown length for various reasons. The clinical crown is that portion of the tooth that extends occlusally or incisally from the investing soft tissue, usually the gingiva (American Academy of Periodontology 1992). Teeth with subgingival caries or shortened by extensive caries, fractures, short clinical crowns with or without

esthetic deficiencies, and teeth shortened by incomplete exposure of the anatomic crown are all candidates for surgical lengthening. Oftentimes, failure to perform surgery prior to margin placement in these situations leads to margins placed too near the alveolar crest, thus invading the biologic width space. Therefore, in the early stages of restorative treatment planning, if the clinician believes that the margin of the final restoration will be ≤ 3 mm from the alveolar bone crest, crown lengthening should be recommended. This can not only be accomplished by surgery but also by orthodontic forced eruption, or a combination of both. Numerous factors may determine if crown lengthening is needed and often, more important, if a particular tooth (or teeth) is indeed a candidate for crown-lengthening surgery. Before proceeding with surgery, the clinician should always first consider whether orthodontic extrusion is appropriate. Failure to consider orthodontic extrusion can lead to poor cosmetic outcomes (i.e. gingival recession, particularly in anterior teeth), poorer crown:root ratios, and loss of bone support on adjacent teeth (Ingber et al. 1977).

Often, caries or lack of tooth structure necessitates bone removal to a point where the periodontal support of the tooth is compromised, a furcation is exposed, or an inadequate crown:root ratio results. If these situations are anticipated, the treatment plan must be reevaluated and the strategic value of the tooth considered. Also, esthetic issues must be evaluated presurgically, particularly if crown lengthening is needed for the anterior teeth.

While many situations require it, crown-lengthening surgery is often underutilized. Because of this, too much reliability is placed on post and core restorations and deep subgingival margin placement to gain adequate retention for restorative purposes (Allen 1993). This often leads to root fractures in the case of post and core restorations, and violation of the biologic width in the case of deep subgingival margins. These factors contribute to greater expense and frustration for the patient, hence further complicating restorative and periodontal therapy.

Surgical methods for crown lengthening include (a) gingivectomy, (b) apically positioned flap surgery (APF), and (c) APF with osseous reduction. Gingivectomy and APF without osseous

reduction are limited because bone removal is often necessary to provide adequate distance from the osseous crest to the anticipated restoration margin, allowing for biologic width. Therefore, APF with osseous surgery is the most common technique for crown-lengthening surgery. APF with osseous surgery consists of a reverse bevel incision and subsequent mucoperiosteal flap reflection. Vertical releasing incisions are often made to allow better access and apical positioning of the flap. Initial incisions may be intrasulcular if gingival width is narrow, or scalloped when gingival width is wide. Generally, an adjacent tooth on each side of the tooth to be lengthened is included in the surgical procedure to allow for proper contour of the gingiva and underlying bone. Initial osseous recontouring is completed with the use of rotary handpieces and then completed with chisels and curettes to achieve the desired reduction while maintaining a scalloped, parabolic bony contour to follow the desired contour of the overlying gingiva. In addition, end cutting burs are currently available that are designed for removing bone with minimal risk of damaging the root.

Most authors agree that a minimum distance of 3 mm is required from the osseous crest to the final restorative margin following a crown-lengthening procedure to allow the margin to finish supragingivally (Bragger et al. 1992). Thus, 3 mm allows for 1 mm of supra-crestal connective tissue attachment, 1 mm of junctional epithelium, and 1 mm for sulcus depth. It should be noted again, however, that 3 mm assumes a biologic width of approximately 2.04 mm, based on Gargiulo’s findings. It is important to remember that there was significant individual variation in Gargiulo’s study, especially at the epithelial attachment. Therefore, it may be more reasonable to allow more than 3 mm between the restorative margin and the crestal bone to allow for individual variation. Wagenberg et al. (1989), in fact, suggested a 5 mm distance from bone to the restorative margin. They clarified that the length of the clinical crown, furcation locations, and esthetic considerations limit surgery. They also advocated waiting 8–12 weeks before final prosthetic treatment. This group noted that bone removal is inherently unnatural to the periodontist and thus clinicians have a tendency to remove too little bone during crown

lengthening procedures. Others have also advocated allowing 5 mm from bone to restoration to ensure adequate osseous reduction. It is felt that 5 mm will allow for individual variations in biologic width dimensions and will prevent the clinician from removing too little bone. The phenomenon of underreduction was recently demonstrated by Herrero et al. (1995). They evaluated the amount of actual surgical crown lengthening achieved during surgery in relation to the desired 3 mm goal. Clinicians of different experience levels performed the lengthening procedures, and a separate examiner completed the measurements before, during, and 8 weeks after surgery. Results demonstrated a mean reduction of 2.4 mm, 0.6 mm less than that required to achieve the 3 mm goal. Also, experienced clinicians achieved greater osseous reduction. The authors concluded that clinicians might need to be more aggressive and take measurements during surgery to achieve their desired goal of osseous reduction. Pontoriero & Carnevale (2001) demonstrated the unwanted effects of minimal osseous reduction during crown-lengthening surgery. Eighty-four teeth underwent crown-lengthening procedures and were followed for 1 year postoperatively. While initially a mean of 3.9 mm of new tooth structure was exposed, 1 year later a mean of 3.05 mm of coronal displacement of the gingival occurred, thus resulting in an overall mean gain of crown length of 0.85 mm. In all these surgical procedures, while the gingival margin was repositioned apically following surgery, minimal osseous reduction was completed (approximately 1 mm). This study demonstrates the importance of adequate alveolar crest reduction in order to allow for a desirable final gingival margin location.

A common problem during crown-lengthening surgery is that the surgeon cannot precisely determine where the restorative dentist will place the final restorative margin. Hence, it is imperative that the surgeon and the restorative dentist communicate prior to treatment. When uncertainty remains, a successful outcome can usually be achieved if the surgeon follows certain basic principles. When an amalgam or composite restoration is planned for a particular tooth, the clinician must allow for approximately 4 mm distance between the apical extent of the planned restorative margin and the alveolar crest. This

distance will account for individual biologic width variations and most likely "assure" that enough space will exist between the bone crest and the eventual restorative margin. For teeth that are planned for post and core restorations, the surgeon should provide at least 5–6 mm of exposed tooth above the osseous crest. This again allows for 4 mm from the alveolar crest to the restorative margin while also accounting for a 1.5 mm ferrule length. The ferrule effect refers to the idea that a 360° metal collar of crown surrounding the parallel walls of the dentin should extend at least 1.5 mm apical to the shoulder of the preparation (Libman & Nicholls 1995).

For teeth planned for crown restorations, generally these cases present with the tooth or portions of the tooth fractured or decayed at the gingival margin. The clinician should provide enough coronal tooth exposure to allow for adequate retention of the crown along with planing for a 4 mm distance from the restorative margin to the alveolar crest. The clinician should also bear in mind that bone resorption usually follows osseous resective surgery. It has been estimated that an additional 0.6–0.8 mm of bone resorption occurs up to 1 year following osseous surgery (Wilderman et al. 1970, Selipsky 1976).

Brägger et al. (1992) completed one of the few controlled studies evaluating periodontal changes in the healing phase after surgical crown lengthening. Twenty-five patients who received surgery were monitored for 6 months. Clinical parameters of 43 test and 42 control teeth were evaluated using an acrylic splint as a reference. The results demonstrated alveolar crest reduction of 1–2 mm following surgery in 53% of cases. 3–4 mm of bone removal was carried out in 4% of cases. Mean tissue recession following surgery was 1.32 mm, while 29% of sites demonstrated 1–4 mm gingival recession between 6 weeks and 6 months postoperatively. Attachment levels or probing depths did not change after 6 weeks of healing (Brägger et al. 1992). This study lends support to the concept of refraining from restorative treatment for at least 6 weeks following crown-lengthening surgery. Furthermore, due to the possibility of recession, delaying margin placement for 6 months following surgery in areas of esthetic concerns may be indicated.

Some investigators have questioned whether the biologic width dimensions return following crown-lengthening procedures. Caton's group observed that following osseous surgery and apically positioned flap, there was a reduced distance between the gingival margin and the apical extent of the junctional epithelium (Caton & Nyman 1981). Also, since it is widely known that osseous surgery results in crestal bone resorption (Wilderman et al. 1970), questions have arisen as to the exact nature of the dento-gingival unit following osseous resective surgery. Oakley et al. (1999) investigated the formation of the dento-gingival unit following crown-lengthening surgery in nonhuman primates. Crown lengthening was performed in the incisor region of three adult monkeys. Histometric analysis revealed that the biologic width is reestablished following the procedure. The junctional epithelium is established at the apical extent of root planing. Space for the supracrestal connective tissue attachment is created by crestal resorption of alveolar bone. This contradicts the views of some authors who opined that the supracrestal connective tissue would reform coronal to the apical extent of root planing, thus necessitating a greater exposure of tooth structure during surgery.

Conclusions

The health of the periodontal tissues is dependent on properly designed restorative materials. Overhanging restorations and open interproximal contacts should be addressed and remedied during the disease control phase of periodontal therapy. Regarding restorative margins, undoubtedly it is preferable if margins can remain coronal to the free gingival margin. Obviously, subgingival margin placement is often unavoidable. However, care must be taken to involve as little of the sulcus as possible. Evidence suggests that even minimal encroachment on the subgingival tissue can lead to deleterious effects on the periodontium. Furthermore, deep margin placement risks invading the soft tissue attachment of the gingiva to the tooth, often leading to a more pronounced plaque-induced inflammatory response. If restorative margins need to be placed near the alveolar crest, crown-lengthening surgery or orthodontic extrusion should be considered to provide ade-

quate tooth structure while simultaneously assuring the integrity of the biologic width. Although individual variations exist in the soft tissue attachment around teeth, there is general agreement that a minimum of 3 mm should exist from the restorative margin to the alveolar bone, allowing for 2 mm of biologic width space and 1 mm for sulcus depth.

Acknowledgments

This work was partially supported by the University of Michigan, Periodontal Graduate Student Research Fund.

Zusammenfassung

Die Beziehungen zwischen der Gingiva und dem Rand von Restaurationen

Das richtige Verständnis der Beziehungen zwischen parodontalen Geweben und der restaurativen Zahnheilkunde ist von höchster Wichtigkeit, um die richtige Form, Funktion, Ästhetik und den Komfort der Dentition zu sichern. Während die meisten Kliniker sich dieser wichtigen Beziehung bewusst sind, bleiben einige Unsicherheiten bezüglich des spezifischen Konzeptes der biologischen Breite und den Indikationen und Anwendungen für die chirurgische Kronenverlängerung. Dieser Reviewartikel diskutiert das Konzept der biologischen Breite und seiner Beziehung zur parodontalen Gesundheit und restaurativen Zahnheilkunde. Die Wichtigkeit der Lokalisation des marginalen Restaurationsrandes, des Materials und der Kontur bezüglich der parodontalen Gesundheit werden ebenso beschrieben. Begründungen und Indikationen für die chirurgische Kronenverlängerung werden ausgearbeitet. Besondere chirurgische Prinzipien der Kronenverlängerung werden im Detail überprüft.

Résumé

Interactions entre la gencive et le bord des restaurations

Comprendre le mieux possible la relation entre les tissus parodontaux et la dentisterie restauratrice est essentiel pour assurer une forme adéquate, une fonction, une esthétique et le confort de la dentition. Bien que la plupart des cliniciens soient attentifs à cette relation importante, l'incertitude reste en ce qui concerne les concepts spécifiques tels que la largeur biologique, les indications et applications pour l'élongation coronaire chirurgicale. Cette revue discute du concept de la largeur biologique et de sa relation avec la santé parodontale et la dentisterie restauratrice. L'importance du placement du bord de la restauration, des matériaux et des contours en relation avec la santé parodontale sont également revus. Les raisons et les indications de l'élongation coronaire

chirurgicale sont analysés. Des principes chirurgicaux particuliers de l'élongation coronaire sont examinés en détail.

References

- Allen, E. P. (1993) Surgical crown lengthening for function and esthetics. *Dental Clinics of North America* **37**, 163–179.
- American Academy of Periodontology (1992) *Glossary of periodontal terms*, 3rd edition, p. 11. Chicago: American Academy of Periodontology.
- Becker, C. M. & Kaldahl, W. B. (1981) Current theories of crown contour, margin placement, and pontic design. *Journal of Prosthetic Dentistry* **45**, 268–277.
- Block, P. L. (1987) Restorative margins and periodontal health. A new look at an old perspective. *Journal of Prosthetic Dentistry* **57**, 683–689.
- Brägger, U., Lauchenaue, D. & Lang, N. P. (1992) Surgical crown lengthening of the clinical crown. *Journal of Clinical Periodontology* **19**, 58–63.
- Brunsvold, M. A. & Lane, J. J. (1990) The prevalence of overhanging dental restorations and their relationship to periodontal disease. *Journal of Clinical Periodontology* **17**, 67–72.
- Caton, J. & Nyman, S. (1981) Histometric evaluation of periodontal surgery. III. The effect of bone resection on the connective tissue attachment level. *Journal of Periodontology* **52**, 405–409.
- Chen, J. T., Burch, J. G., Beck, F. M. & Horton, J. E. (1987) Periodontal attachment loss associated with proximal tooth restorations. *Journal of Prosthetic Dentistry* **57**, 416–420.
- Dragoo, M. R. & Williams, G. B. (1981) Periodontal tissue reactions to restorative procedures, Part I. *International Journal of Periodontics and Restorative Dentistry* **2**, 8–29.
- Dragoo, M. R. & Williams, G. B. (1982) Periodontal tissue reactions to restorative procedures, Part II. *International Journal of Periodontics and Restorative Dentistry* **2**, 34–42.
- Ehrlich, J. & Hochman, N. (1980) Alterations on crown contour – effect on gingival health in man. *Journal of Prosthetic Dentistry* **44**, 23–525.
- Flores-de-Jacoby, L., Zafropoulos, G. G. & Cianco, S. (1989) The effect of crown margin location on plaque and periodontal health. *International Journal of Periodontics and Restorative Dentistry* **9**, 197–205.
- Gargiulo, A. W., Wentz, F. & Orban, B. (1961) Dimensions and relations of the dentogingival junction in humans. *Journal of Periodontology* **32**, 261–267.
- Gilmore, N. & Sheiham, A. (1971) Overhanging dental restorations and periodontal disease. *Journal of Periodontology* **42**, 8–12.
- Gunay, H., Seeger, A., Tschernitschek, H. & Geurtsen, W. (2000) Placement of the preparation line and periodontal health – a prospective 2-year clinical study. *International Journal of Periodontics and Restorative Dentistry* **20**, 171–181.
- Hancock, E. B., Mayo, C. V., Schwab, R. R. & Wirthlin, M. R. (1980) Influence of interdental contacts on periodontal status. *Journal of Periodontology* **51**, 445–449.
- Herrero, F., Scott, J. B., Maropis, P. S. & Yukna, R. A. (1995) Clinical comparison of desired versus actual amount of surgical crown lengthening. *Journal of Periodontology* **66**, 568–571.
- Highfield, J. E. & Powell, R. N. (1978) Effects of removal of posterior overhanging metallic margins of restorations upon the periodontal tissues. *Journal of Clinical Periodontology* **5**, 169–181.
- Ingber, J. S., Rose, L. F. & Coslet, J. G. (1977) The biologic width'' – a concept in periodontics and restorative dentistry. *Alpha Omega* **70**, 62–65.
- Jeffcoat, M. K. & Howell, T. H. (1980) Alveolar bone destruction due to overhanging amalgam in periodontal disease. *Journal of Periodontology* **51**, 599–602.
- Kepic, T. J. & O'Leary, T. J. (1978) Role of marginal ridge relationships as an etiologic factor in periodontal disease. *Journal of Periodontology* **49**, 570–575.
- Lang, N. P., Kiel, R. A. & Anderhalden, K. (1983) Clinical and microbiological effects of subgingival restorations with overhanging or clinically perfect margins. *Journal of Clinical Periodontology* **10**, 563–578.
- Larato, D. (1971) Relationship of food impaction to interproximal intrabony lesions. *Journal of Periodontology* **42**, 237–238.
- Libman, W. J. & Nicholls, J. I. (1995) Load fatigue of teeth restored with cast posts and cores and complete crowns. *International Journal of Prosthodontics* **8**, 155–161.
- Maynard, J. G. & Wilson, R. D. K. (1979) Physiologic dimensions of the periodontium significant to the restorative dentist. *Journal of Periodontology* **50**, 170–174.
- Nevins, M. & Skurow, H. M. (1984) The intracrevicular restorative margin, the biologic width, and the maintenance of the gingival margin. *International Journal of Periodontics and Restorative Dentistry* **3**, 31–49.
- Newcomb, G. M. (1974) The relationship between the location of subgingival crown margins and gingival inflammation. *Journal of Periodontology* **45**, 151–154.
- Oakley, E., Rhyu, I. C., Karatzas, S., Santiago, L. G., Nevins, M. & Caton, J. (1999) Formation of the biologic width following crown lengthening in nonhuman primates. *International Journal of Periodontics and Restorative Dentistry* **19**, 529–541.
- Orkin, D. A., Reddy, J. & Bradshaw, D. (1987) The relationship of the position of crown margins to gingival health. *Journal of Prosthetic Dentistry* **57**, 421–442.
- Pack, A. R., Coxhead, L. J. & McDonald, B. W. (1990) The prevalence of overhanging margins in posterior amalgam restorations and periodontal consequences. *Journal of Clinical Periodontology* **17**, 145–152.

- Parma-Benfenati, S., Fugazzotto, P. A., Ferreira, P. M., Ruben, M. P. & Kramer, G. M. (1986) The effect of restorative margins on the postsurgical development and nature of the periodontium. Part II. Anatomical considerations. *International Journal of Periodontics and Restorative Dentistry* **6**, 65–75.
- Pontoriero, R. & Carnevale, G. (2001) Surgical crown lengthening: a 12-month clinical wound healing study. *Journal of Periodontology* **72**, 841–848.
- Renggli, H. H. & Regolati, B. (1972) Gingival inflammation and plaque accumulation by well-adapted supra-gingival and sub-gingival proximal restorations. *Hel Odontol Acta* **16**, 99–101.
- Selipsky, H. (1976) Osseous surgery – how much need we compromise? *Dental Clinics of North America* **20**, 79–106.
- Silness, J. (1980) Fixed prosthodontics and periodontal health. *Dental Clinics of North America* **24**, 317–329.
- Spinks, G. C., Carson, R. E., Hancock, E. B. & Pelleu, G. B. Jr (1986) An SEM study of overhang removal methods. *Journal of Periodontology* **57**, 632–636.
- Stetler, K. & Bissada, N. (1987) Significance of the width of keratinized gingival on the periodontal status of teeth with submarginal restorations. *Journal of Periodontology* **58**, 696–700.
- Tal, H., Soldinger, M., Dreiangel, A. & Pitaru, S. (1989) Periodontal response to long-term abuse of the gingival attachment by supra-cresal amalgam restorations. *Journal of Clinical Periodontology* **16**, 654–659.
- Vacek, J. S., Gehr, M. E., Asad, D. A., Richardson, A. C. & Giambarresi, L. I. (1994) The dimensions of the human dento-gingival junction. *International Journal of Periodontics and Restorative Dentistry* **14**, 154–165.
- Valderhaug, J. & Birkeland, J. M. (1976) Periodontal conditions in patients 5 years following insertion of fixed prostheses. *Journal Oral Rehabilitation* **3**, 237–243.
- Waerhaug, J. (1980) Temporary restorations: advantages and disadvantages. *Dental Clinics of North America* **24**, 305–306.
- Wagenberg, B. D., Eskow, R. N. & Langer, B. (1989) Exposing adequate tooth structure for restorative dentistry. *International Journal of Periodontics and Restorative Dentistry* **5**, 321–332.
- Wang, H-L., Burgett, F. G. & Shyr, Y. (1993) The relationship between restoration and furcation involvement on molar teeth. *Journal of Periodontology* **64**, 302–305.
- Wilderman, M. N., Pennel, B. M., King, K. & Barron, J. M. (1970) Histogenesis of repair following osseous surgery. *Journal of Periodontology* **41**, 551–565.
- Yuodelis, R. A., Weaver, J. D. & Sapkos, S. (1973) Facial and lingual contours of artificial complete crown restorations and their effects on the periodontium. *Journal of Prosthetic Dentistry* **29**, 61.

Disclaimers: The authors do not have any financial interests, either directly or indirectly, in the products listed in the study.

Address:
 Hom-Lay Wang
 Department of Periodontics/
 Prevention/Geriatrics
 University of Michigan School of Dentistry
 1011 North University Avenue
 Ann Arbor, MI 48109-1078
 USA
 Fax: (734) 936-0374
 e-mail: homlay@umich.edu