

# Common Pediatric Skin Disorders

By Jill Keddy-Grant, MD, FRCPC  
Section Head, Pediatric Dermatology  
Department of Pediatrics and Child Health  
University of Manitoba

# Conflicts of Interest

- Member of Advisory Board for:
  - CeraVe Line funded by Valeant
  - Hemangirol funded by Pierre Fabre
- Participating in a clinical study looking at the long term safety of Protopic - Funded by Leo
- Participated in the clinical studies for Elidel
- Contributor to a Consensus Group on Atopic Dermatitis funded by Pfizer

## Objectives:

After this session, participants should know:

- How to manage and when to refer patients with atopic eczema
- Which hemangiomas require treatment
- How to differentiate and manage a variety of conditions that present with white spots

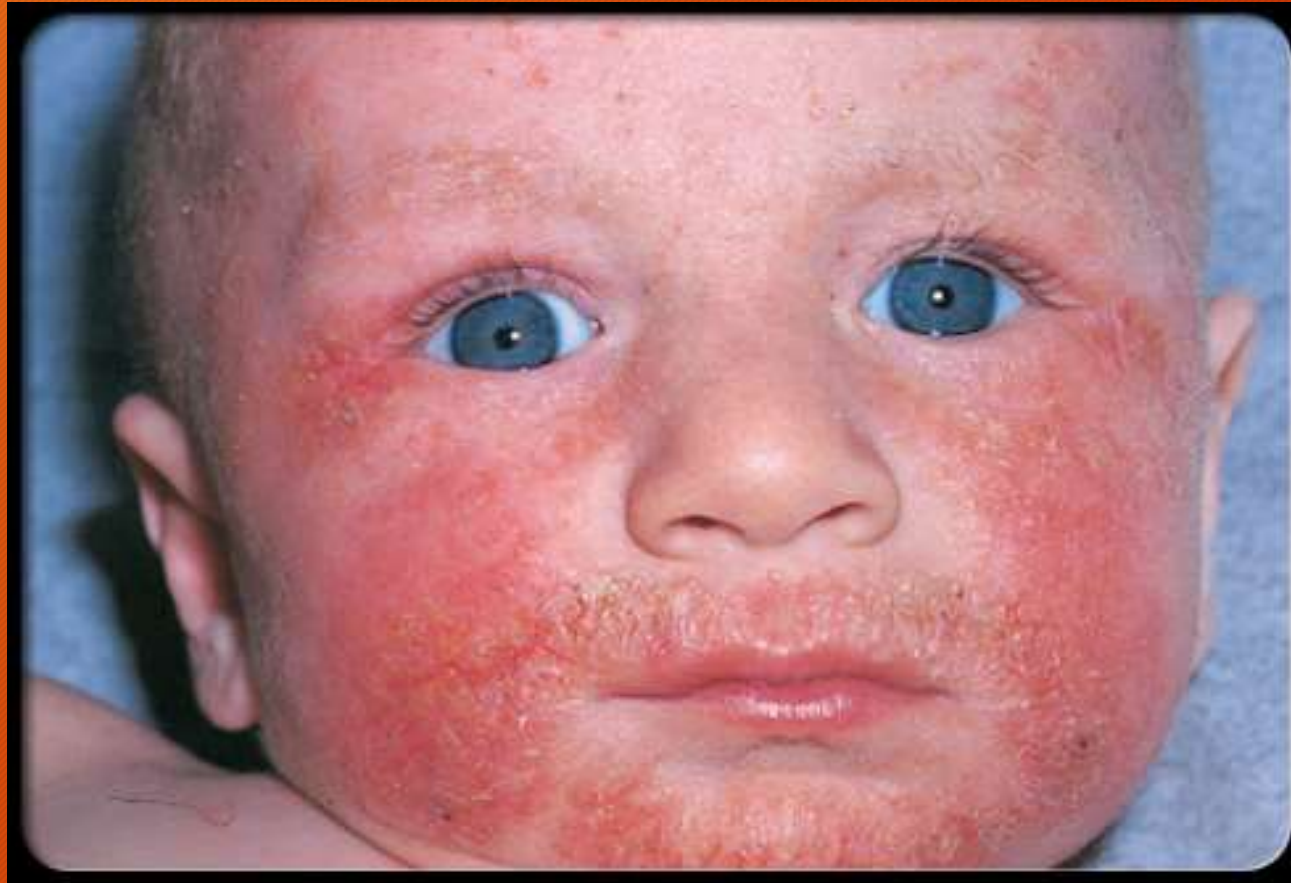# Atopic Dermatitis

- **An eczematous eruption that usually presents in infancy**
- **Forms part of the triad of allergic rhinitis and asthma (atopy)**
- **Affects 10-30% of children**
- **80-90% diagnosed by age 5**
- **75% improve by age 14**
- **25% carry on into adulthood**

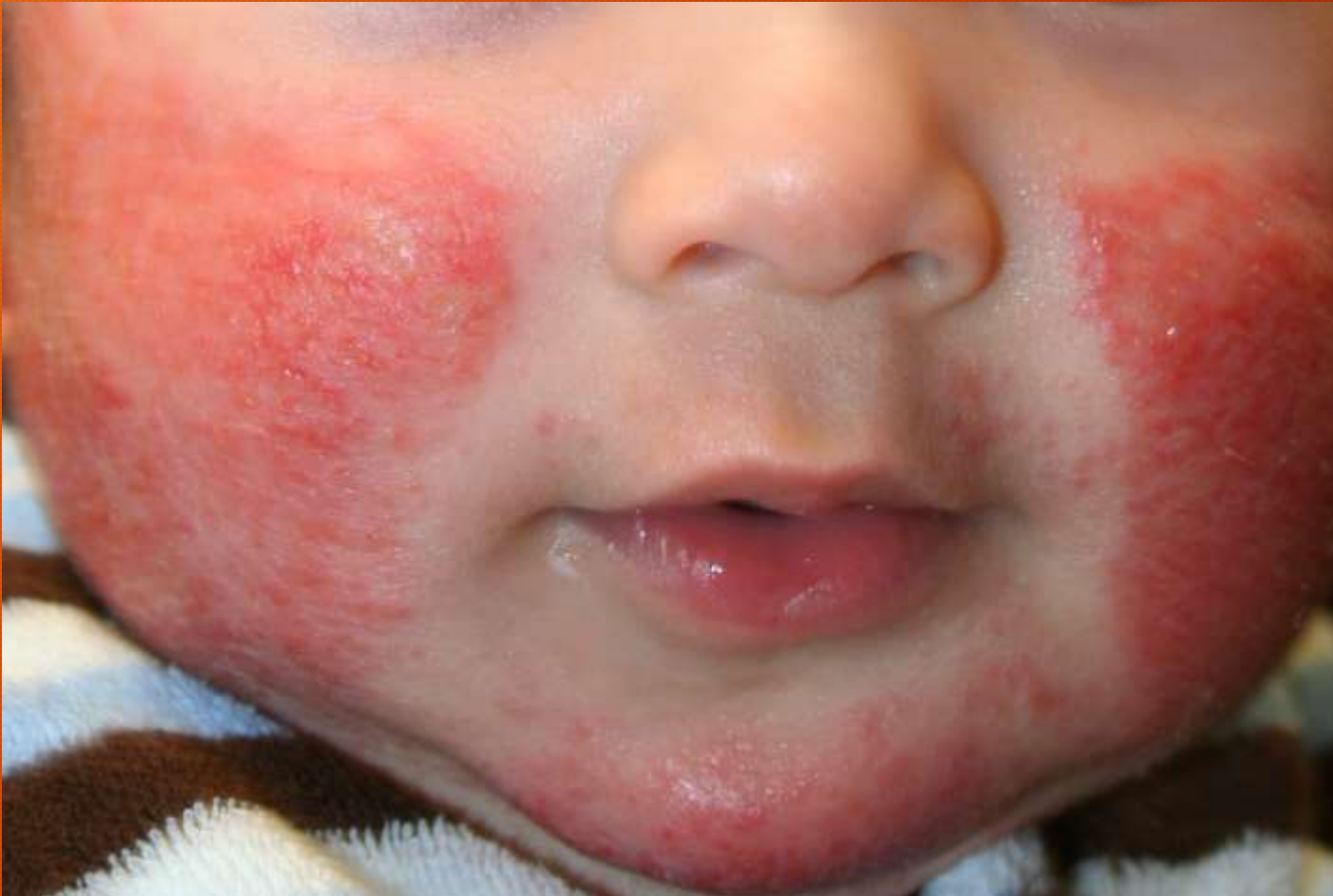# Diagnosis of Atopic Dermatitis

- **Hanifin and Rajka Classification (1980):**
- **Must have 3 or more basic features**
  - Pruritus
  - Typical morphology and distribution
    - Facial and extensor eruption in infants
    - Flexural lichenification in children and adults
  - Chronic or chronically relapsing dermatitis
  - Personal or family history of atopy (asthma, allergic rhinitis, eczema)
- **Must have 3 or more minor features (23)**
  - Xerosis
  - Early Age of Onset

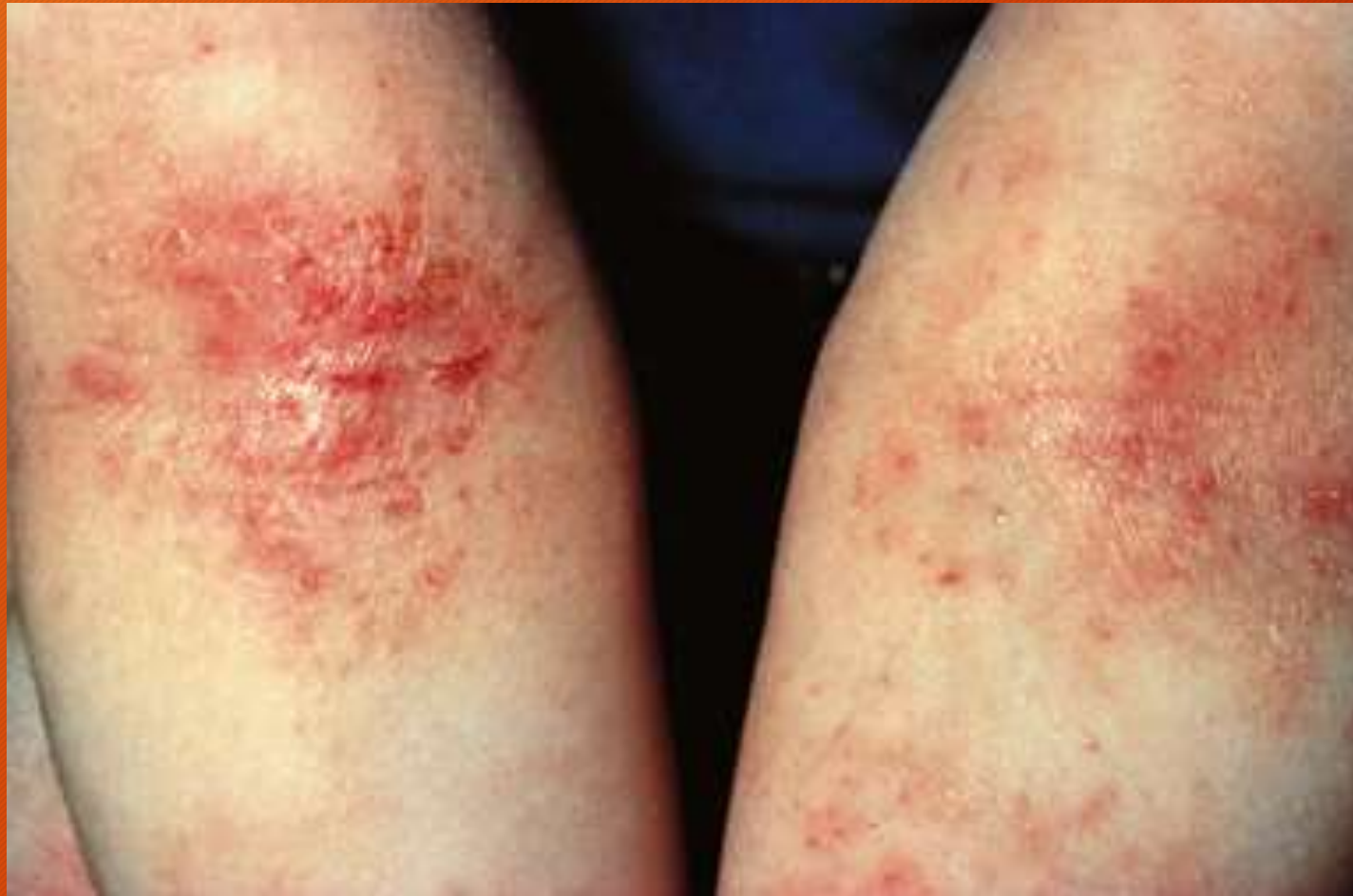# Infantile Atopic Eczema



# Infantile Atopic Eczema



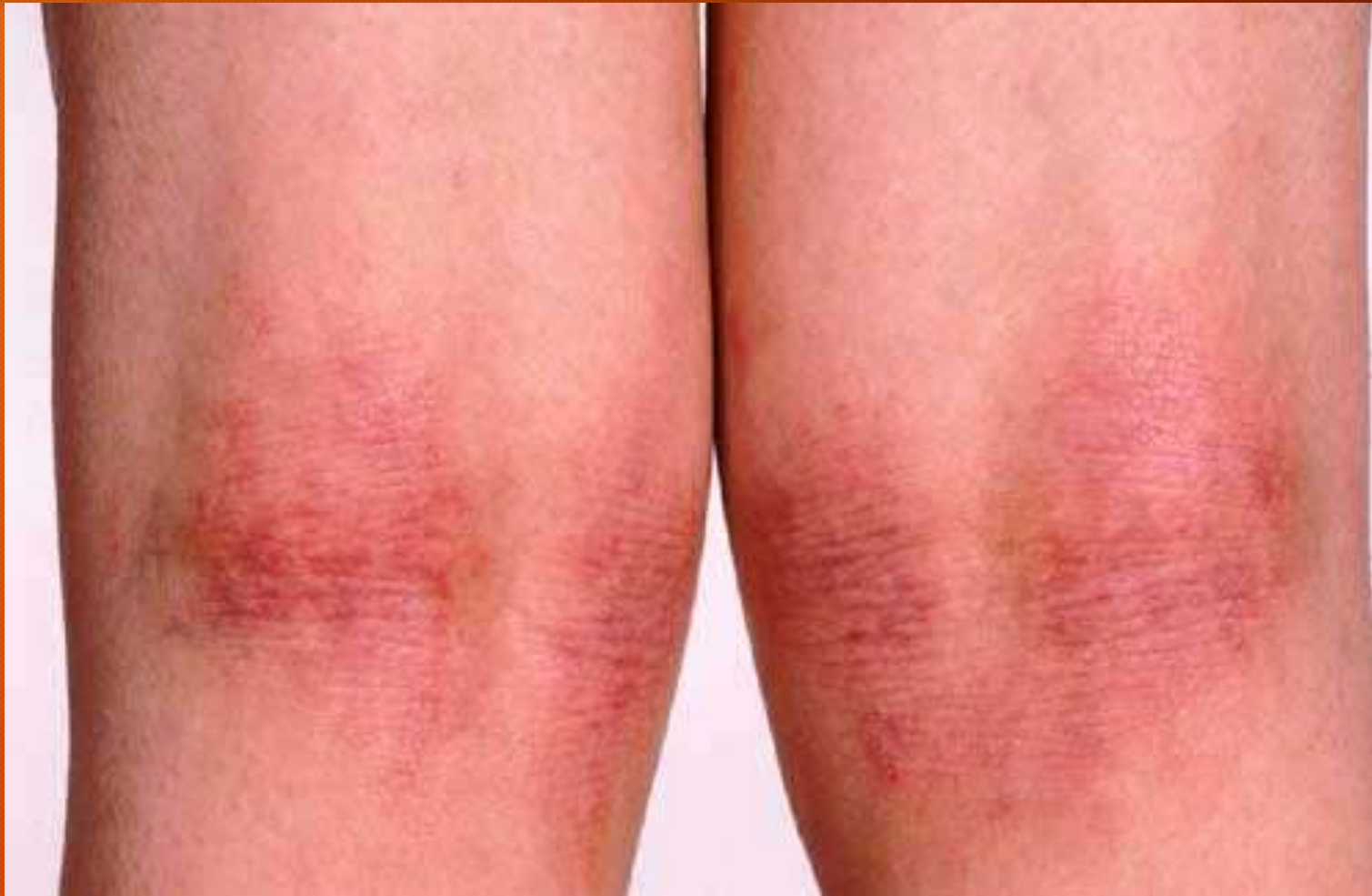# Childhood and Adult Atopic Eczema Flexural



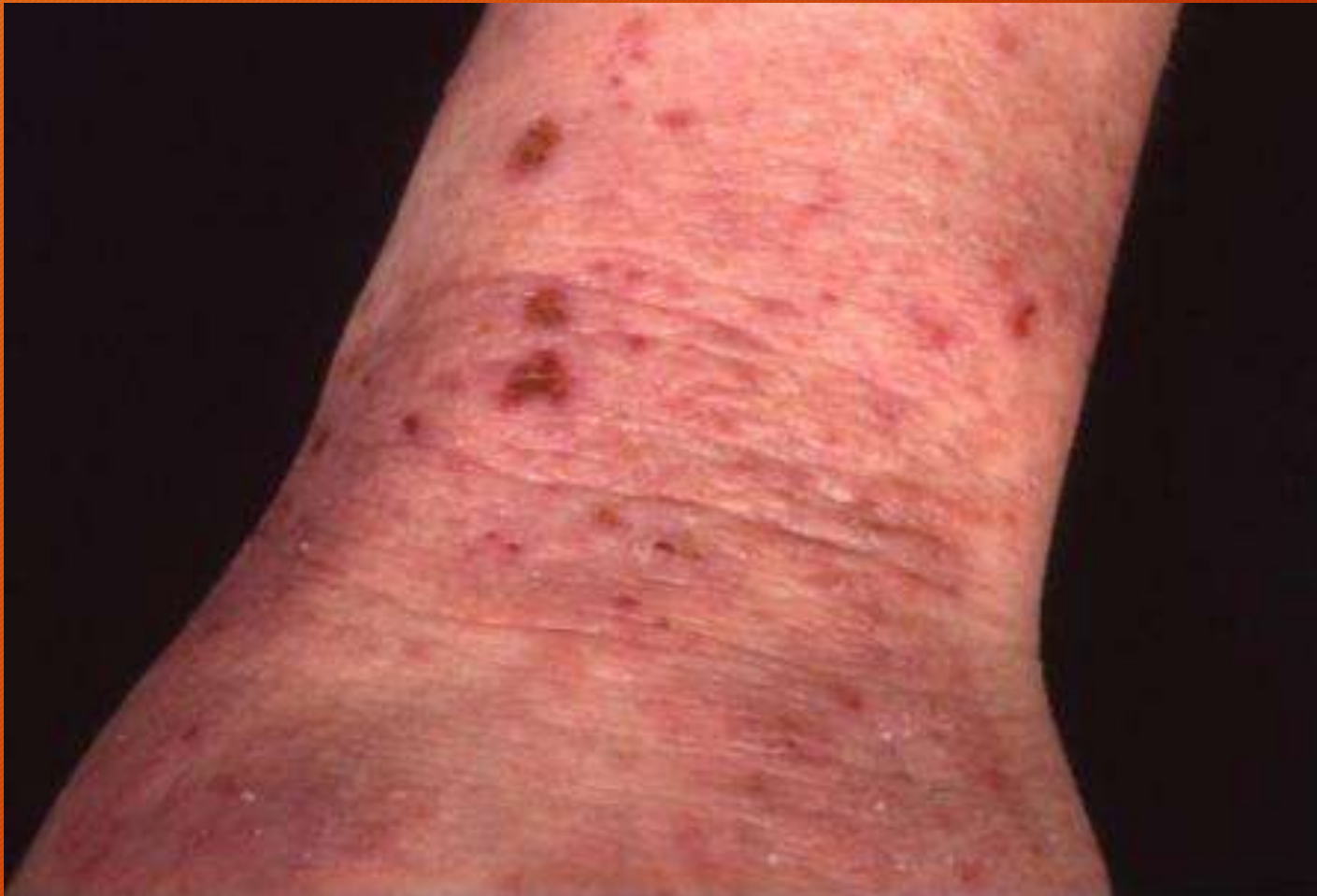

# Childhood and Adult Atopic Eczema

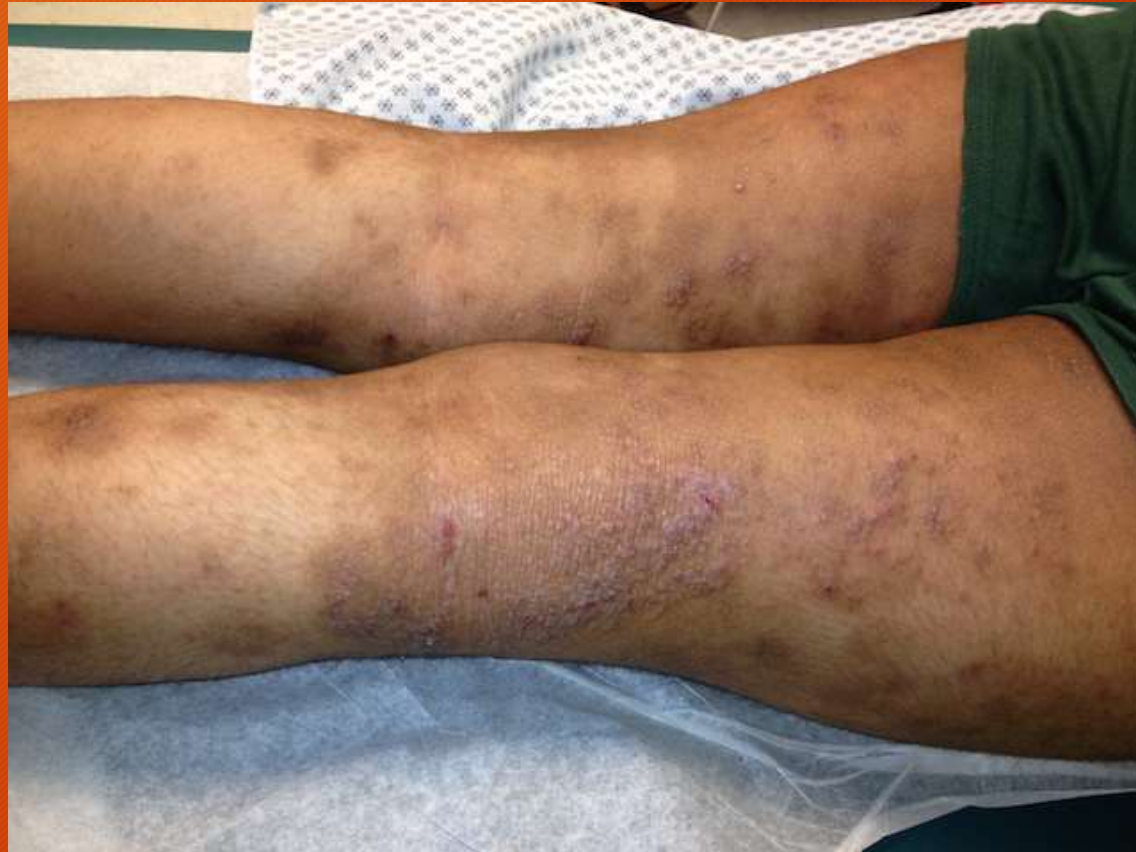## Lichenification



# Childhood Atopic Eczema Lichenification/ Excoriations



# Childhood Atopic Eczema Post-inflammatory Hyperpigmentation



# Pathogenesis of Atopic Dermatitis

- **Barrier Defects**
  - Reduced ceramide and filaggrin levels
  - Affects permeability and water-holding capacity
- **Disordered Immune Response**
  - Excessive Th2 cell activation in response to antigen - IL4 and IL13 in acute lesions, IL5, IL12 and gamma IFN in chronic lesions
  - Chronic lesions have increased eosinophils
  - Elevated serum IgE levels
- **Altered Microbiome**
  - Increased Staph. aureus - less microbial diversity
  - Reduced Staph. epidermidis

# Pathogenesis of Atopic Dermatitis

- **Multiple factors initiate and perpetuate the barrier defects and the inflammation:**
  - **dryness – temperature and humidity**
  - **irritants – clothes, soap, water, sweat, chlorine etc.**
  - **pruritus – scratching**
  - **infection – Staph. aureus**
  - **allergens**
    - **foods – milk, egg, peanuts, soy, wheat, and fish**
    - **aeroallergens – dust mites, pollens, molds, danders**
  - **stress**

# Management of Atopic Eczema: Education

- Education of the parents and child is key
  - Complicated treatment regimens
  - Poor adherence to treatment - time consuming, \$, poor understanding
- This is a chronic disease
- Many factors play a role
- It must be managed just like asthma
- No formal education programs at present
- Good websites - Eczema Society of Canada
- Handouts
- Return visits to review general measures and treatment

# Management of Atopic Eczema

## Correct the Dryness

- Cochrane Review showed moisturizing was a cornerstone of treatment - reduced flares and reduced need for topical steroids
- Moisturize with cream or ointment at least twice a day - hypoallergenic (ex. Glaxal Base®, Cetaphil® cream, CeraVe® cream, Vaseline Creamy® or Petroleum Jelly, Lipikar AP®, Aveeno® Eczema Cream)
- Start early - Reduces incidence of atopic eczema by 50%
- Bathing interval - controversial
- Bathe with soapless cleanser - (Ex. Cetaphil®, CeraVe®, Aveeno® Body Wash, Dove® Body Wash)
- Humidifier

# Management of Atopic Eczema: Remove Irritants

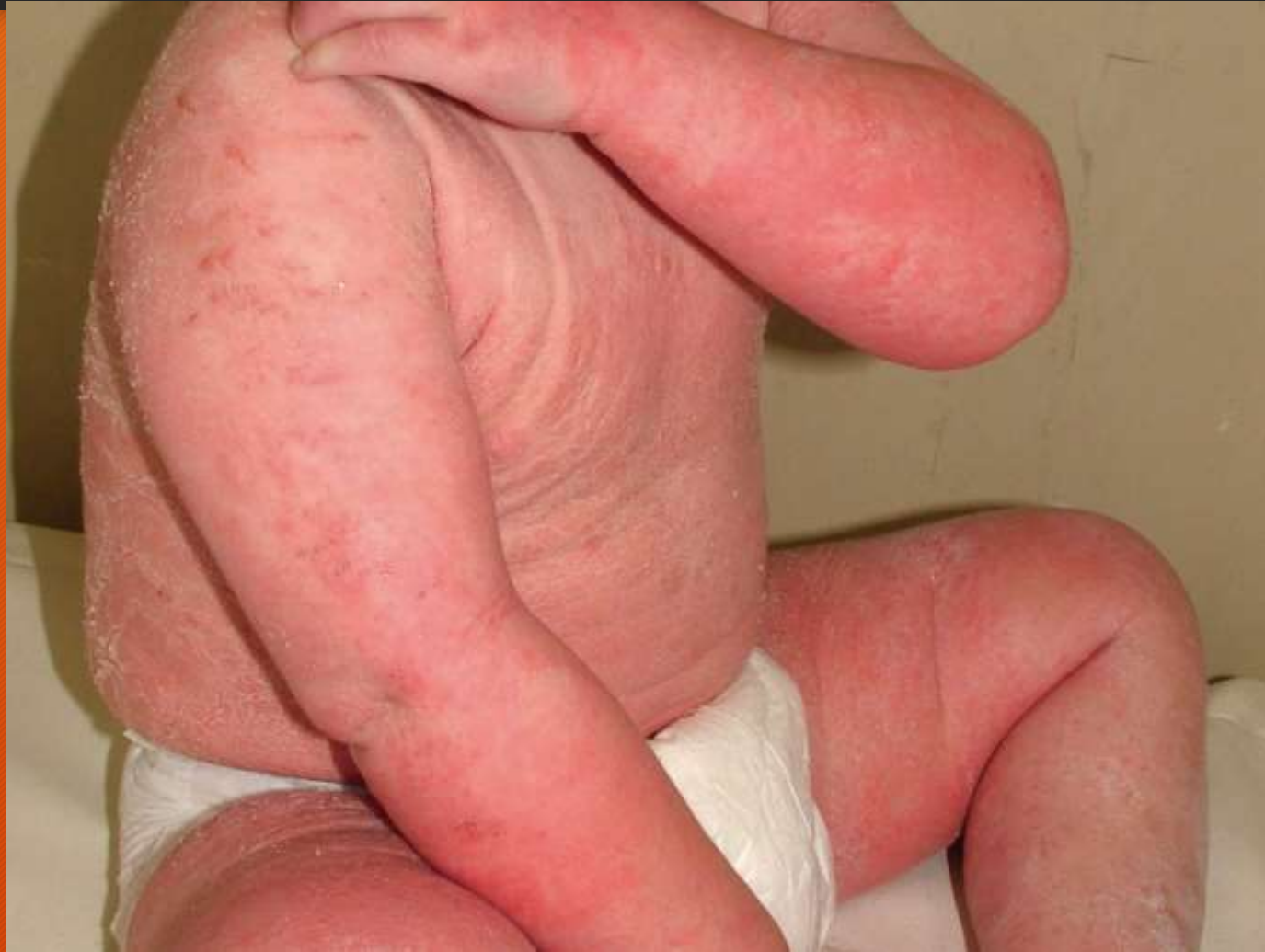- Sweat - frequent bathing, bathing after sports, keep cool
- Detergents - Ivory Snow®, Tide Free and Gentle®, Purex Free and Clear®, Arm and Hammer® etc.
- Clothing - 100% soft cotton or blends with polyester, no wool
- Chlorine - no hot tubs, swim during summer months, salt water pools
- Heat - air conditioning, fan at night, light cotton pyjamas, light bedding (no feather duvets), cool pillow?



# Management of Atopic Eczema: Consider Allergens

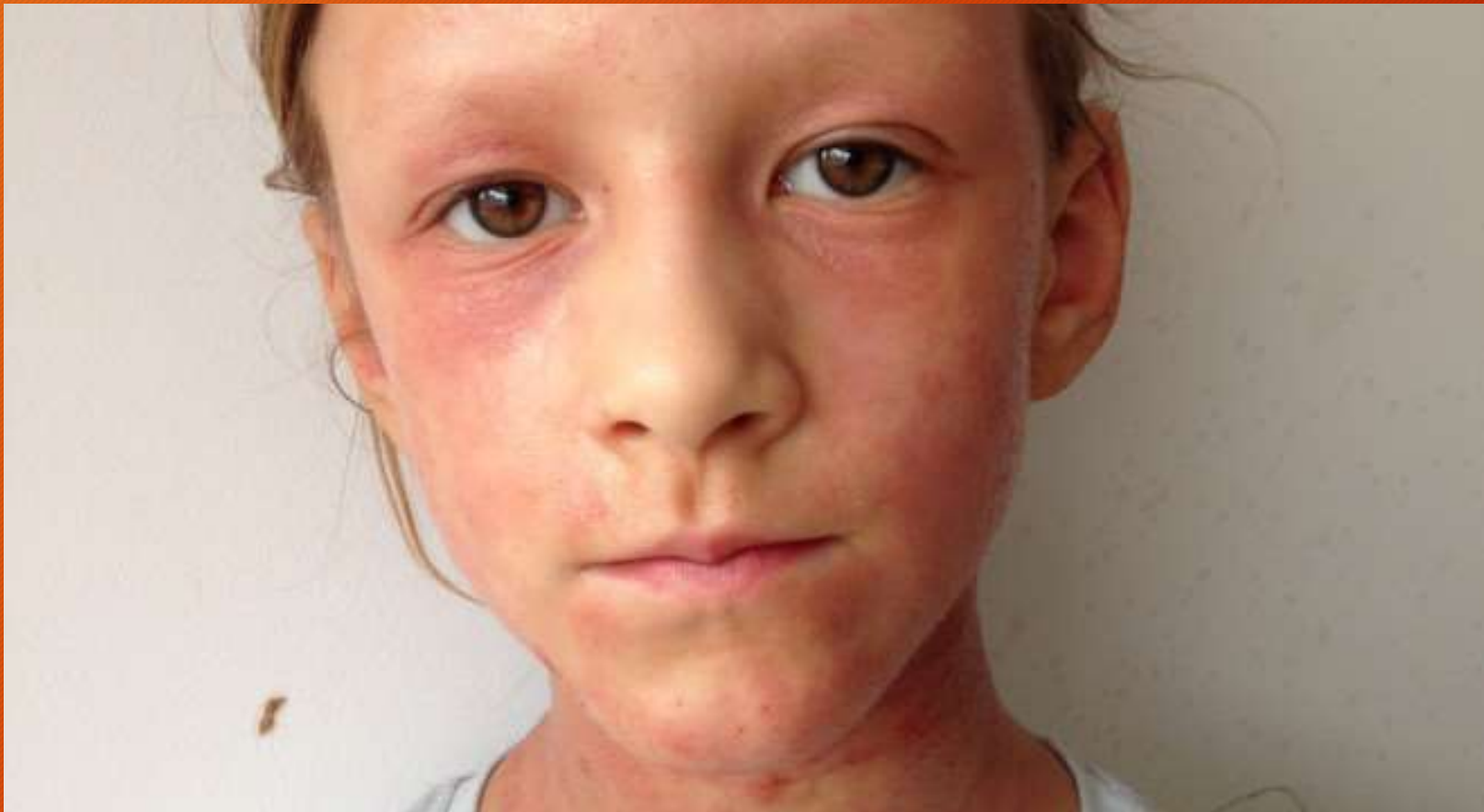- If allergies are suspected, refer to a pediatric allergist
- Infants -
  - milk - Nutramigen®, Alimentum®, Neocate®
  - soy
  - eggs
- Children -
  - dust mites - eliminate carpets and curtains, dust mite covers for bed and pillow
  - grass - long pants and shoes with socks
  - pets - give away, keep out of child's room
  - environmental factors - limit time outdoors, oral antihistamine

# Infantile Atopic Eczema - ? Allergens

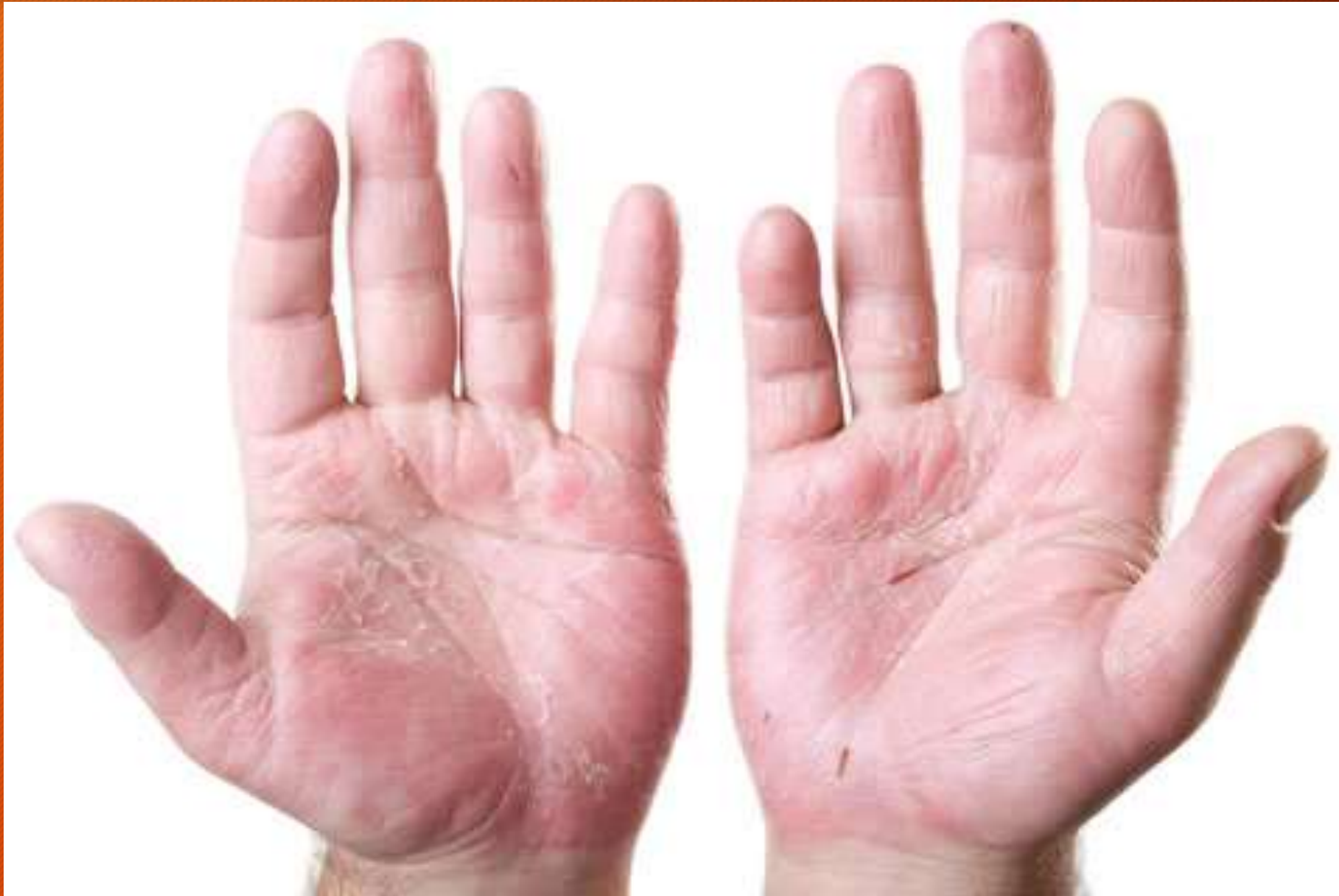

# Childhood Atopic Eczema - ? Allergens

## Facial/ Periocular Involvement



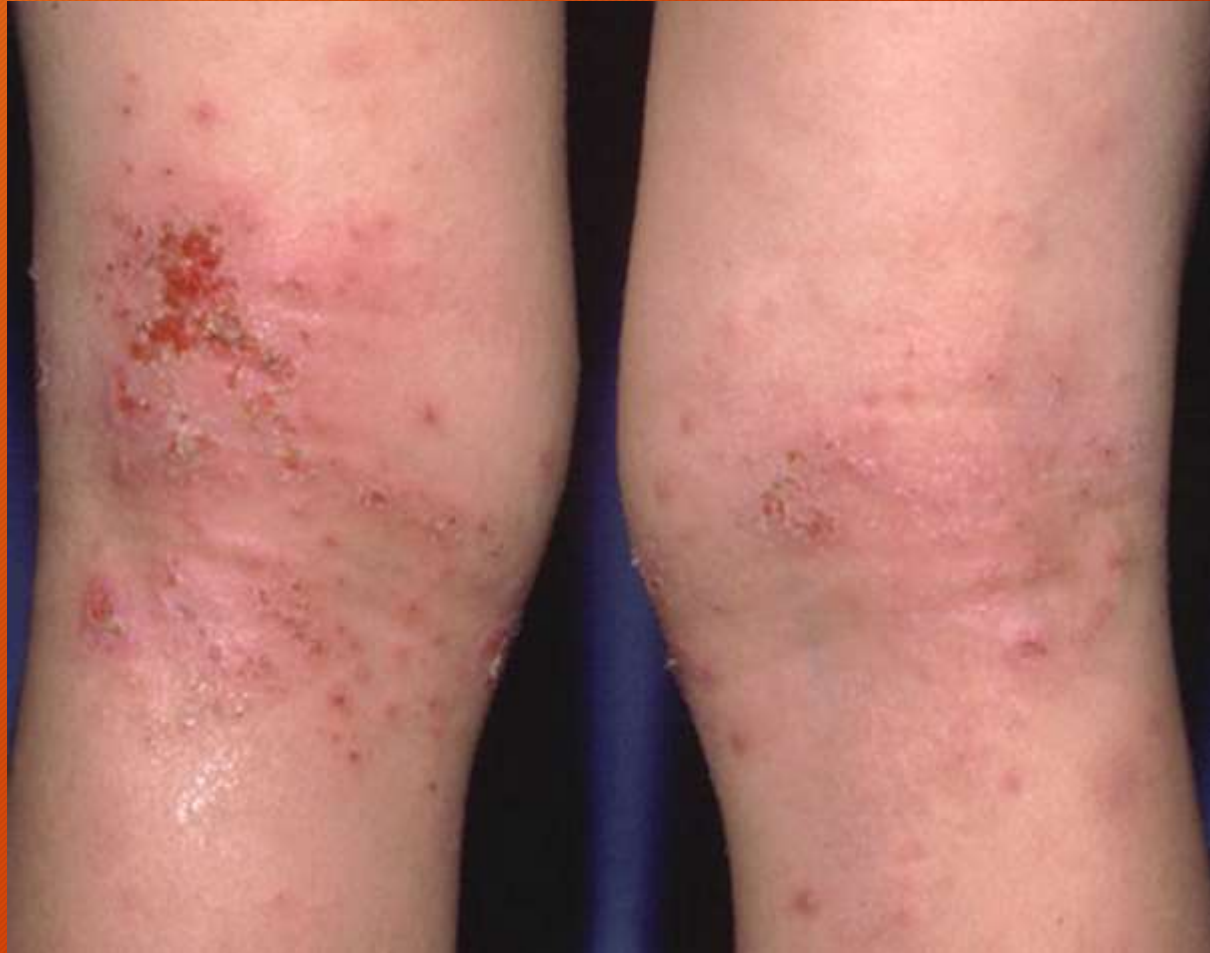# Adult Atopic Eczema - ? Allergens



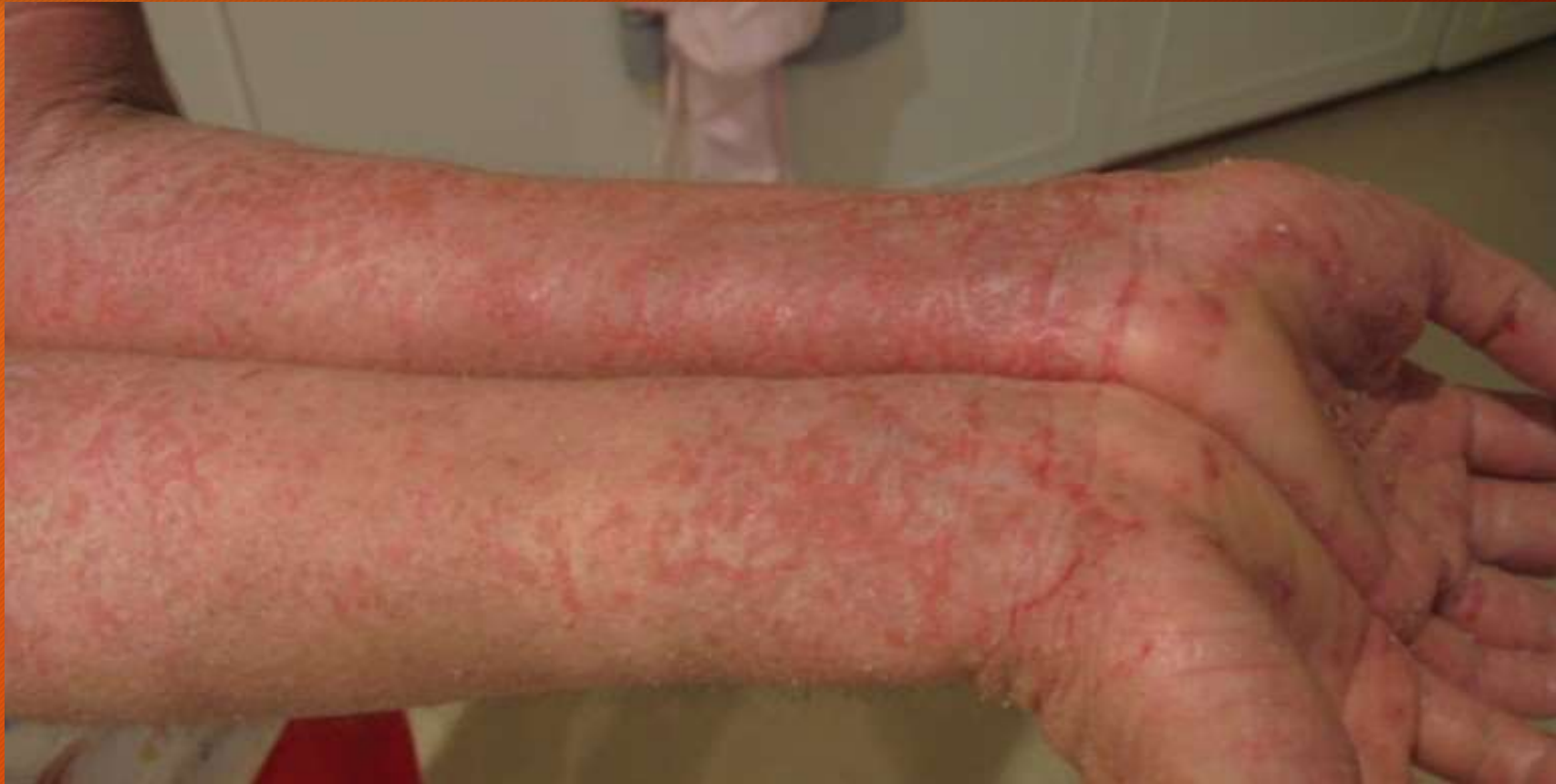# Management of Atopic Eczema: Infection

- Usually Staph. Aureus (MSSA and MRSA), occasionally Strep
- High incidence in the First Nations population
- Treat with topical or oral antibiotics
- Bleach baths - 3 times a week
  - 2 TBSP in baby tub, ¼ cup in ¼ tub of water, ½ cup in ½ tub of water
- Decolonize household if frequent - intranasal Mupirocin or Fucidic acid oint BID for 1 - 2 weeks
- Clean house with bleach - floors, countertops, door knobs, toys, bathroom

# Atopic Eczema - Infection



# Childhood Atopic Eczema



# Management of Atopic Eczema: Pruritus / Scratching

- Treatment of the atopic eczema - topical steroids, calcineurin inhibitors
- Keep cool
- Antihistamines - Hydroxyzine, Diphenhydramine, Bilastine (Blexten®†). If environmental allergies contribute - non sedating antihistamines may help (Desloratidine, Loratidine, Cetirizine)
- Anti itch creams - contain pramoxine, menthol or oatmeal -ex. Aveeno® and Gold Bond® Anti Itch lotion
- Wet wraps

†J. Dermatology. 2017 Apr;44(4): 375-385



# Management of Atopic Eczema: Inflammation

- Topical steroids
- Topical calcineurin inhibitors
- Tar
- Phototherapy - Narrow Band UVB
- Systemic agents - MTX, Cyclosporin, Azothiaprine
- Newer treatments - IL4 (Dupilumab) and IL13 inhibitors, JAK inhibitors, PDE4 inhibitor - oral (Apremilast) and topical (Crisaborole - Eucrisa)

# Management of Atopic Dermatitis

## Topical Corticosteroids

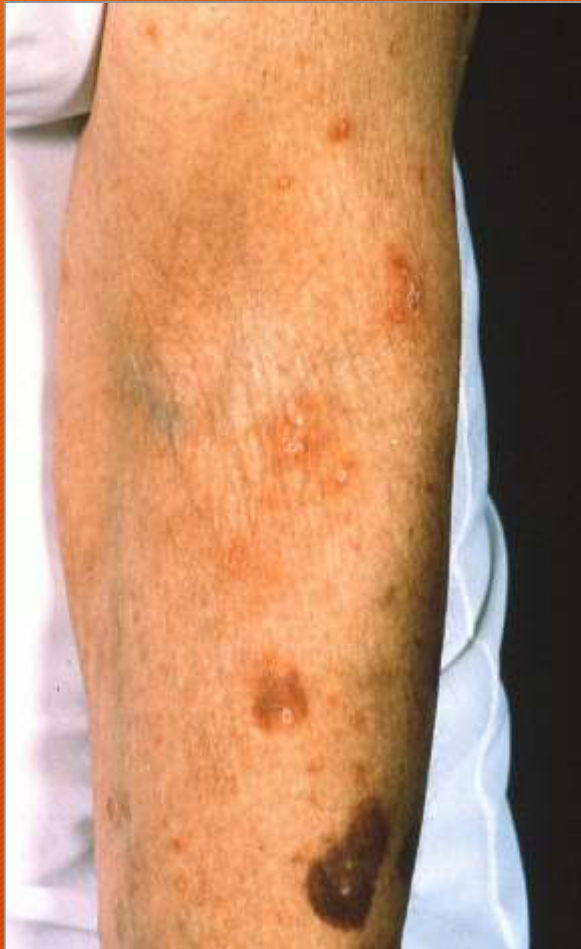- First line treatment
- Excellent at reducing inflammation
- Does not correct the barrier defect and higher potency corticosteroids may impair the barrier further
- Use the lowest potency that controls the eczema
- Generally use 1% Hydrocortisone for the face and folds
- May use mid potency corticosteroids on the torso and limbs ex. Betamethasone valerate
- Role for corticosteroids twice a week as maintenance

# Topical Corticosteroids - Risks and Drawbacks

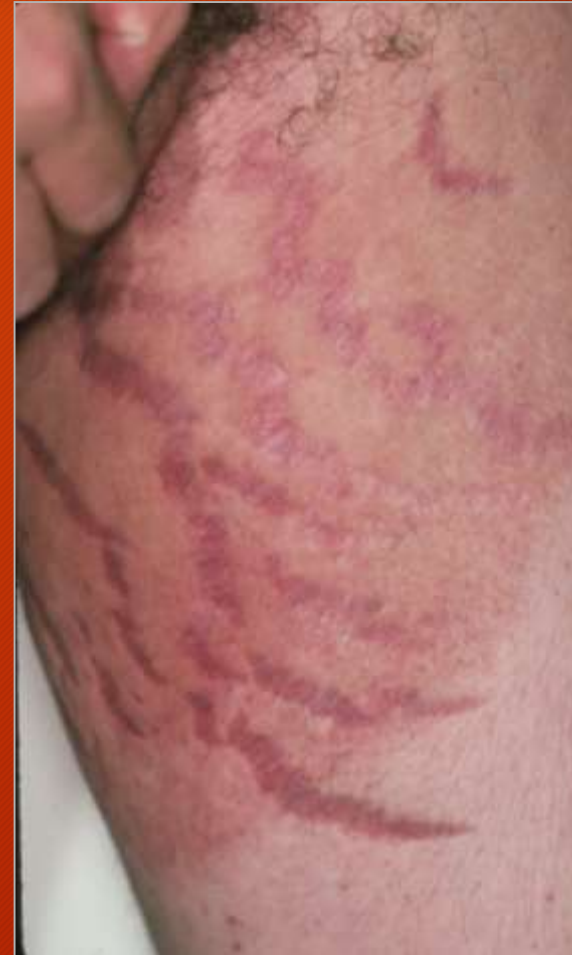- **Cutaneous**
  - Skin atrophy / striae
  - Telangiectasia, pigmentation abnormalities
  - Acne, rosacea-like eruptions
- **Systemic**
  - HPA axis suppression
  - Growth retardation
  - Cushing's syndrome
- **Tachyphylaxis (loss of efficacy with use)**
- **Ocular Toxicity**
- **Steroid phobia**

# Topical Corticosteroid Side Effects

- Atrophy



- Striae



# Calcineurin Inhibitors

## Tacrolimus and Pimecrolimus

- Prevents the activation and proliferation of T cells
  - Blocks production of proinflammatory cytokines including IL2
- Down regulates IgE receptors on Langerhans cells
  - Decreases antigen recognition
- Inhibits release of inflammatory mediators
  - Eg. Histamine from mast cells and basophils
- This all decreases inflammation in the dermis and epidermis
- Leads to improved barrier function
- There is no skin atrophy

# Tacrolimus ointment (Protopic®)

- Topical formulation of the oral transplant drug - FK506
- Approved Sept 2001
- Indication
  - Twice daily application for short and long term intermittent treatment of moderate to severe eczema
  - Twice weekly maintenance therapy to prevent flares or prolong flare free intervals
- Dosage
  - Adults - 0.03% or 0.1% BID
  - Children aged 2 - 15 years - 0.03% BID

# Pimecrolimus cream (Elidel®)

- Specifically developed and formulated to treat eczema
- Ascomycin Macrolactam derivative
- Approved March 2003
- Indication
  - Twice daily application for short and long term intermittent treatment of mild to moderate eczema
- Dosage
  - 1% for adults and children > 2

# Pimecrolimus Safety and Efficacy

- Review in Clinical Therapeutics found:
- 1% Pimecrolimus cream improves the signs and symptoms of AD and delayed time to major flare in patients with mild to moderate AD
- Considered safe:
  - Most common adverse event was application site reactions (burning, pruritus)
  - No substantial increase in common bacterial and viral infections
  - Not associated with skin atrophy
  - No photosensitivity potential
  - No effects on the systemic immune system



# Tacrolimus: Safety and Efficacy

- Cochrane Database Systemic Review found:
- Tacrolimus .1% was better than low potency TCS, Pimecrolimus and Tacrolimus .03%
- Tacrolimus .03% was better than low potency TCS and Pimecrolimus
- Results were equivocal when comparing Tacrolimus .1 and .03% to moderate or potent TCS
- No increased risk of malignancy or skin atrophy
- Main side effect was application site reactions (burning, pruritus)

# Calcineurin Inhibitors: Discussion Points

- Side effect of burning and stinging
  - May need to settle inflammation with a steroid first
  - Excellent for maintenance
  - Side effect decreases with use
- Infection - Do not use if skin is infected
- Cost
  - On EDS list
  - Covered by NIHB
- Black Box Warning
  - Long term safety has not been established - rare reports of skin cancer and lymphoma

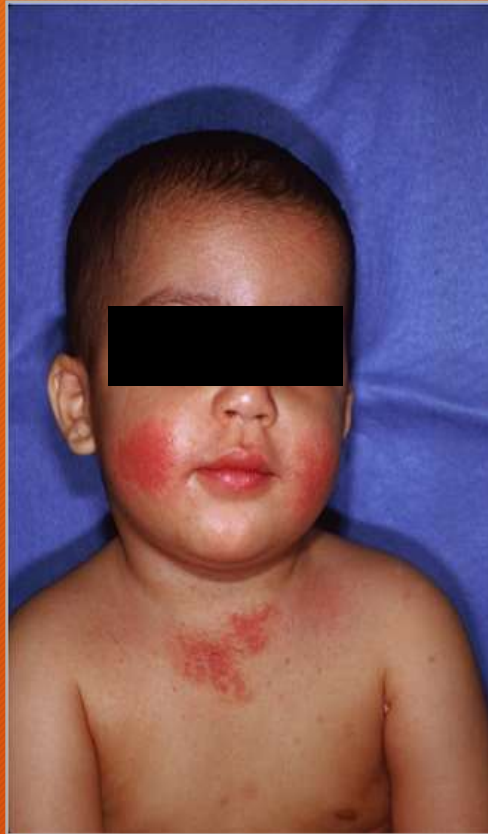# Canadian Dermatology Association: Position on Safety Warning

- No evidence of increased rate of lymphoma with topical calcineurin inhibitors when compared to the general population
- Minimal absorption of topical calcineurin inhibitors, with no detectable or negligible blood levels, making long-term immunosuppression unlikely
- No evidence of interference with effectiveness of immunizations

# Off-label Uses for Tacrolimus

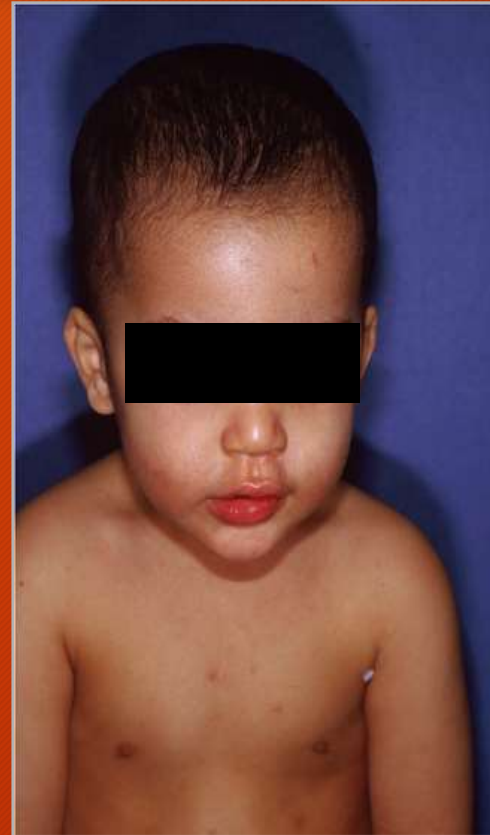- Use in infants < 2 year of age
  - Prospective and retrospective trials demonstrating efficacy, safety and low systemic accumulation following treatment of children < 2 yrs with atopic dermatitis with topical tacrolimus 0.03 and 0.1%
- Use of 0.1% in children < 15 years of age
  - 3 long term, open label, non comparative studies in children 2 - 15 years with 12 months, 29.5 months and 4 year follow up
  - Protopic 0.1% was safe and effective for the treatment of atopic dermatitis; no loss of efficacy over time

# Elidel<sup>®</sup> treatment success



Baseline

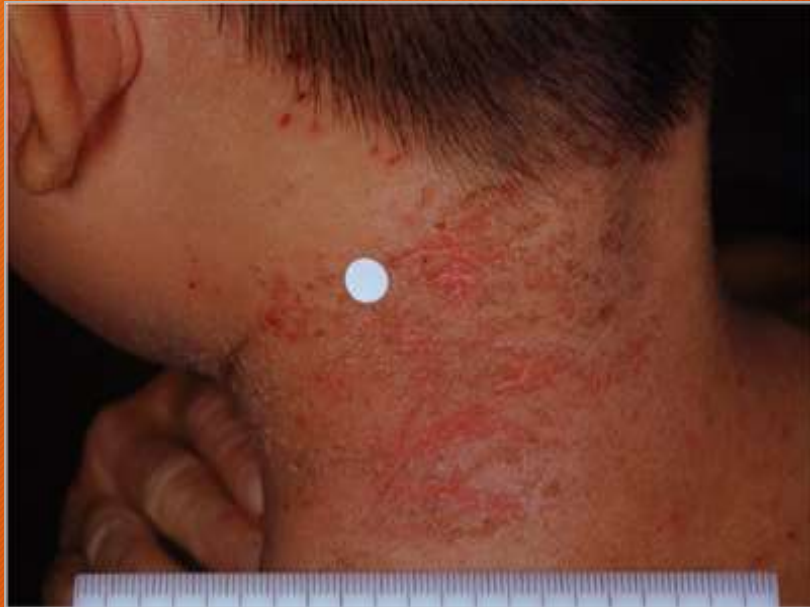**2-year-old  
male**



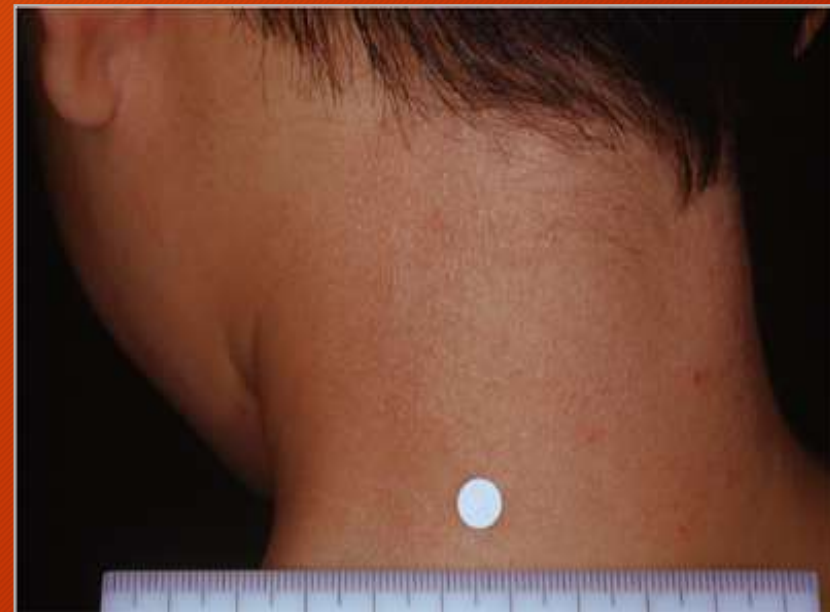End of study – Week  
6

# Elidel<sup>®</sup> treatment success

3-year-old male



Baseline



End of study – week

6

# Atopic Eczema - Summary of New Key Points

- Education of the parent and child is important in the management of atopic dermatitis
- Moisturizing is very important - start early
- Calcineurin inhibitors are very effective and very safe - They can be used in sensitive areas such as face, lips, eyelids and folds
- Maintenance treatment is needed for those with more than 5 flares / year
  - TCS 2 times a week
  - Tacrolimus 2 - 3 times a week
- Refer to dermatology if condition is not well controlled or if parents request

# Hemangiomas

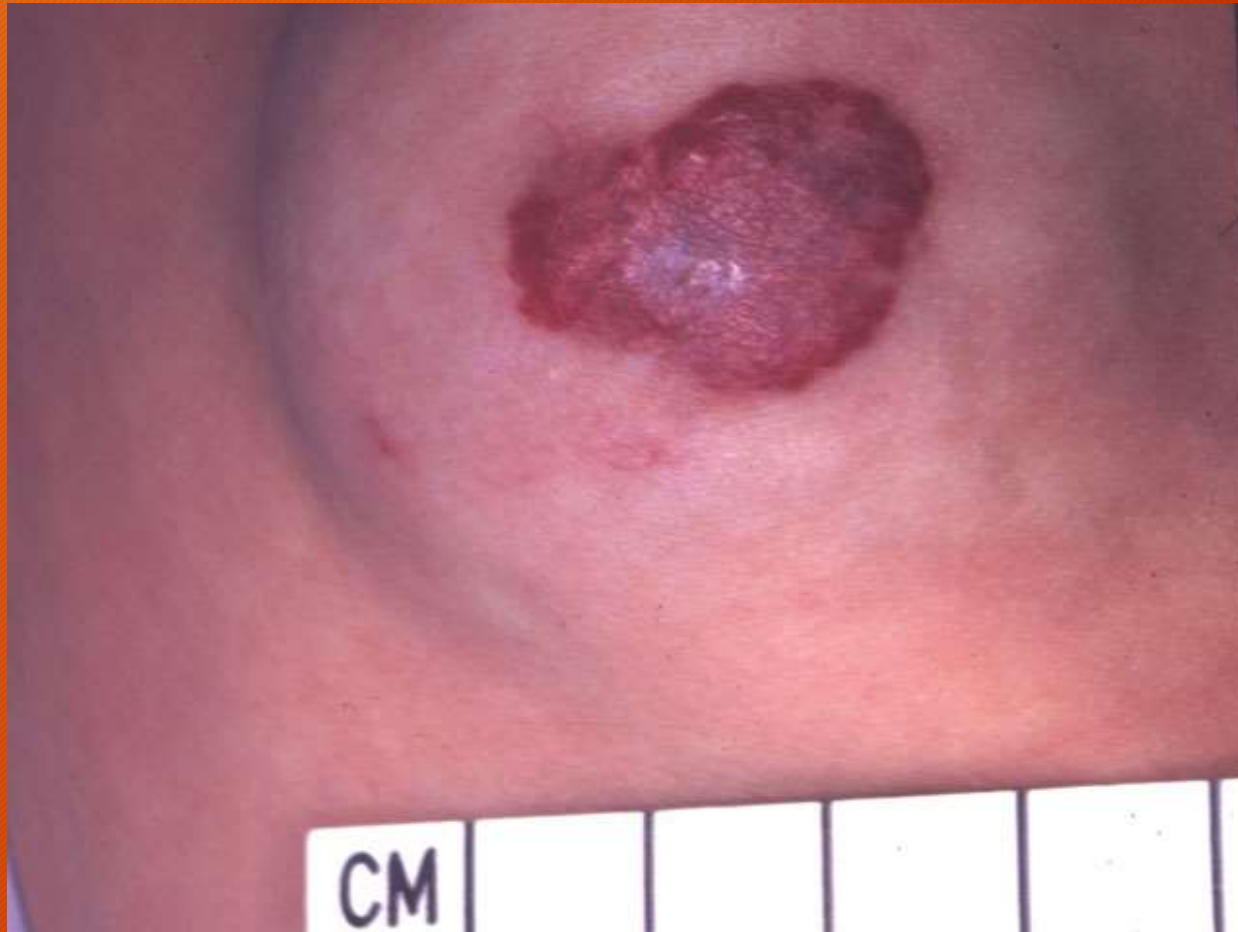- Classified as a tumor rather than a malformation by ISSVA
- Proliferative lesions of the endothelial cells - biopsy is positive for Glut 1
- Cause is unknown - several theories ? Intrauterine hypoxia
- Seen in 10% of infants - (females, low birth wt./premature, multiple births, advanced maternal age, family history)
- Usually not visible at birth - telangiectasias, bruise type lesion, pallor or ulcer
- Grows rapidly after birth
- 80% are on the head and neck



# Hemangiomas - Types

- **Superficial**
  - Upper layers of skin
  - Red plaques, papules or nodules
- **Deep**
  - Deeper layers of skin and sub Q
  - Blue, soft or firm swelling
  - Often prominent veins or telangiectasias on surface
- **Mixed**
  - Both superficial and deep component

# Superficial and Deep Hemangioma



# Hemangioma - Phases

- **Growth phase**
  - Rapid growth from a few weeks to 5 months
  - Slower growth from 5 to 12 months
  - May continue to grow up to 24 months
- **Plateau phase**
  - Usually after 12 months
- **Involutional phase**
  - Superficial lesions change to dull red or grey
  - Deep lesions become smaller, less warm and more compressible
  - 50% gone by 5 years, 90% gone by 9 years

# Hemangiomas After Resolution

- Telangiectasias
- Atrophy
- Loose skin
- Fibrofatty tissue
- Scarring especially if ulcerated

# Hemangiomas - Treatment 10 years ago

- None
- Topical or IL steroids
- Oral steroids - 2 - 4 mg/kg
- Alpha interferon - spastic diplegia
- Vincristine
- Laser for ulcerated lesions
- Corrective surgery

# Hemangiomas - Treatment

- Correspondence in the New England Journal of Medicine June 12, 2008 by several physicians in France (Leaute-Labreze et al):
- “Propranolol for Severe Hemangiomas of Infancy”
- Reported on 11 children with severe hemangiomas
- Given Propranolol 2 mg/ kg / day
- 24 hours after initiation - hemangiomas changed from intense red to purple and softened
- Hemangiomas continued to improve until they were nearly flat

# Hemangiomas - Treatment

- Numerous reports, case series and studies of Propranolol for hemangiomas since 2008
- Now first line therapy for hemangiomas of concern
- One RCT reported in the NEJM in 2015 assessing the efficacy and safety of Propranolol solution
  - 456 patients aged 1 - 5 months
  - Randomized to placebo or 4 groups with Propranolol (1 and 3 mg, 3 and 6 mos)
  - 3 mg / kg / day for 6 months was found to be the best regimen (88% success vs. 5% for placebo)
  - 10% required retreatment after treatment was discontinued
  - Hypoglycemia, hypotension, bradycardia and bronchospasm were infrequent with no significant difference between the treatment and placebo groups

# Hemangiomas - Treatment with Propranolol

- Best dose and treatment schedule is not known
- Start early
- Dose is generally 2 mg / kg divided BID to TID
- Start with 1 mg / kg and then increase to 2 mg / kg
  - Monitor HR, BP and blood sugar for 2 hours after first dose at 1 and 2 mg / kg
- Treat for 6 months or until 12 months of age
- May taper over 2 - 3 months
- Occasionally has to be reintroduced for a few more months



# Propranolol - Side Effects

- Hypoglycemia
- Hypotension
- Bradycardia
- Bronchial hyper reactivity
- Seizure
- Restless sleep - nightmares
- Constipation
- Cold extremities
- Ineffectiveness of epinephrine for anaphylactic reactions

# Nadolol

- Concern about Propranolol causing CNS effects on short and long term memory, psychomotor function, sleep and mood
- Report in Pediatric Dermatology Sept. 2015 by Dr. Elena Pope in Toronto using Nadolol in 44 patients with Hemangiomas
- Less lipophilic than Propranolol so less in the brain and less nightmares
- Well tolerated and effective .5 - 1 - 2 mg / kg
- Main side effect was sleep disturbance

# Hemangiomas - When To Treat

- **No**
  - Small, non critical area
- **Maybe**
  - Small or medium sized in a cosmetically sensitive area
  - Consider topical Timolol .5% gel BID - several reports
  - One study with 73 pts† , all improved except one
  - Best if superficial and treated for > 3 months
- **Yes**
  - Function threatening
  - Ulcerated
  - Syndromic

Timolol Maleate 0.5% Gel-Forming Solution for Infantile Hemangiomas: A Retrospective, Multicenter, Cohort Study. Pediatric Dermatology Jan. 2012,, Pope et. al

# Hemangiomas of Concern: Function Threatening

- Periocular - Loss of vision
- Nasal Tip - Destruction of cartilage
- Periauricular - Destruction of cartilage, obstruction of the ear canal
- Labial - Interference with feeding, risk of ulceration and scarring
- Beard/Submandibular area - Obstruction of the airway

# Hemangiomas of Concern: Ulceration

- Reasons for concern:
  - Pain
  - Bleeding
  - Infection
  - Resultant scarring and deformity
- Locations at Risk
  - Lips
  - Folds
  - Perineal area
  - Rapidly growing hemangiomas

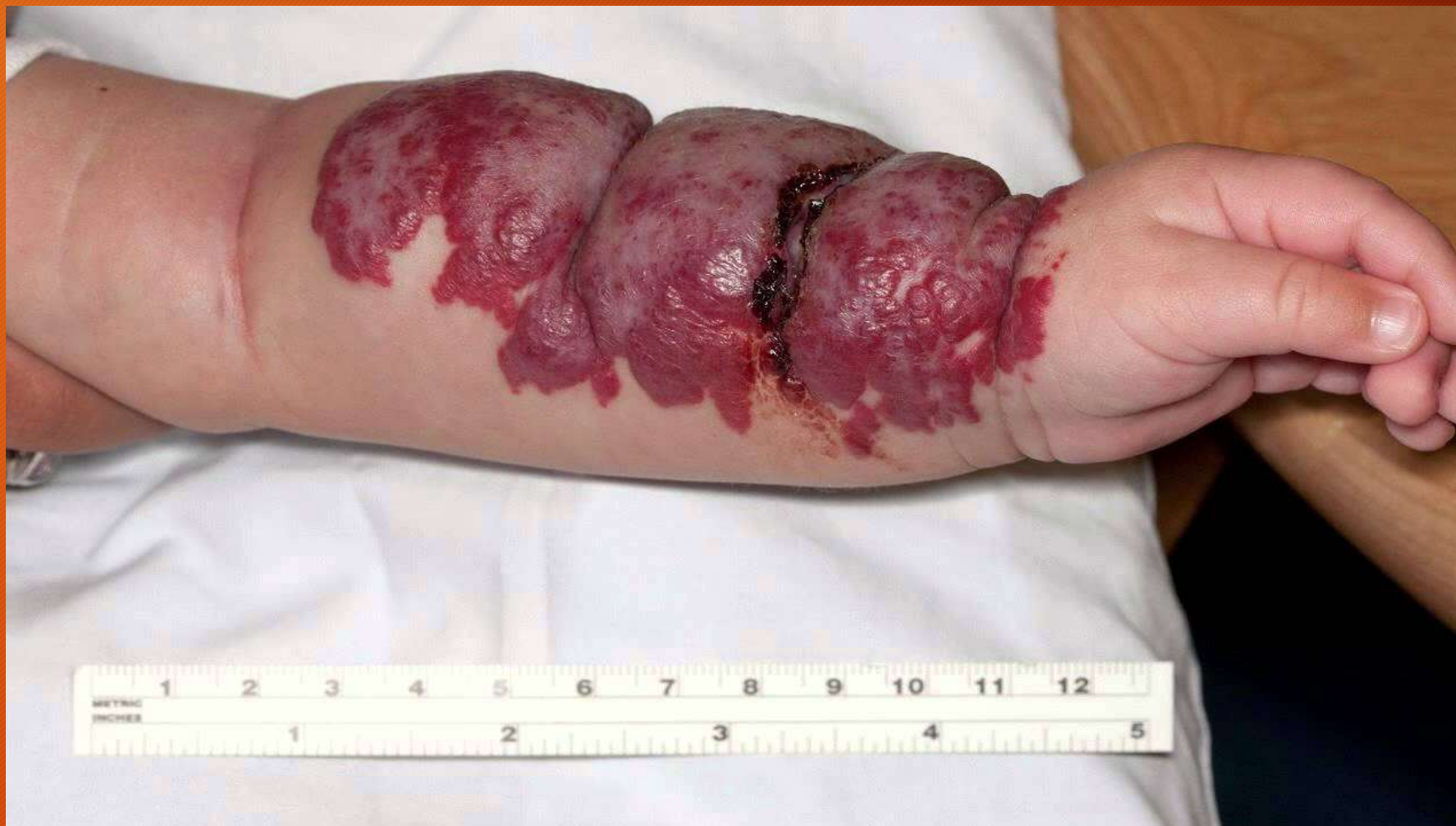# Hemangiomas of Concern: Syndromic

- Large Facial Hemangiomas - PHACES syndrome - posterior fossa abnormalities, hemangioma of face, scalp or neck, arterial anomalies, cardiac defects, eye abnormalities, sternal defects/ supraumbilical raphe
- Large Perineal Hemangiomas - LUMBAR or PELVIS syndrome
  - Lumbar hemangioma, urogenital abn, myelopathy, bone deformities, anorectal malformations / arterial anomalies, renal anomalies
  - Perineal hemangioma, external genitalia abn, lipomyelomeningocele, vesicorenal abn, imperforate anus, skin tag
- Lower Spinal Hemangiomas - tethered cord or spinal dysraphism
- Multiple - If greater than 5 - Risk of internal hemangiomas esp. in the liver. Cardiac overload

# Hemangiomas - Investigations

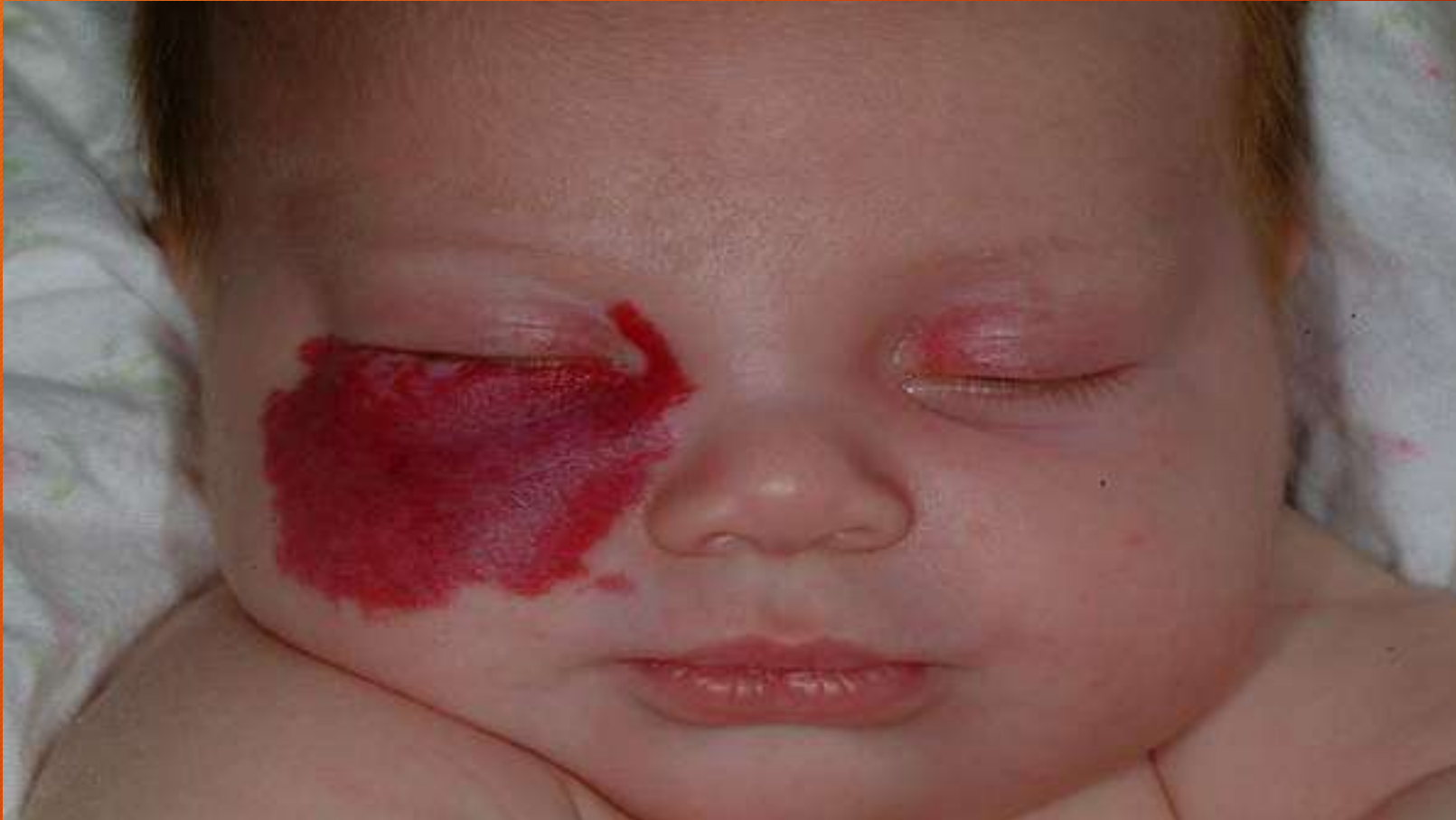- Superficial and localized hemangiomas usually do not require investigation
- Deep may require an ultrasound to differentiate from vascular malformations
- Segmental forms require investigations to rule out associated abnormalities - PHACES (MRI of head and chest with angiography ECHO, ophthalmology consult), PELVIS/LUMBAR (U/S or MRI of abdomen, pelvis and lower spine)
- Hemangiomas over the lower spine require US or MRI to rule out spinal dysraphism or tethered cord
- Multiple hemangiomas require an ultrasound of the abdomen - liver

# Large Hemangioma - Ulceration

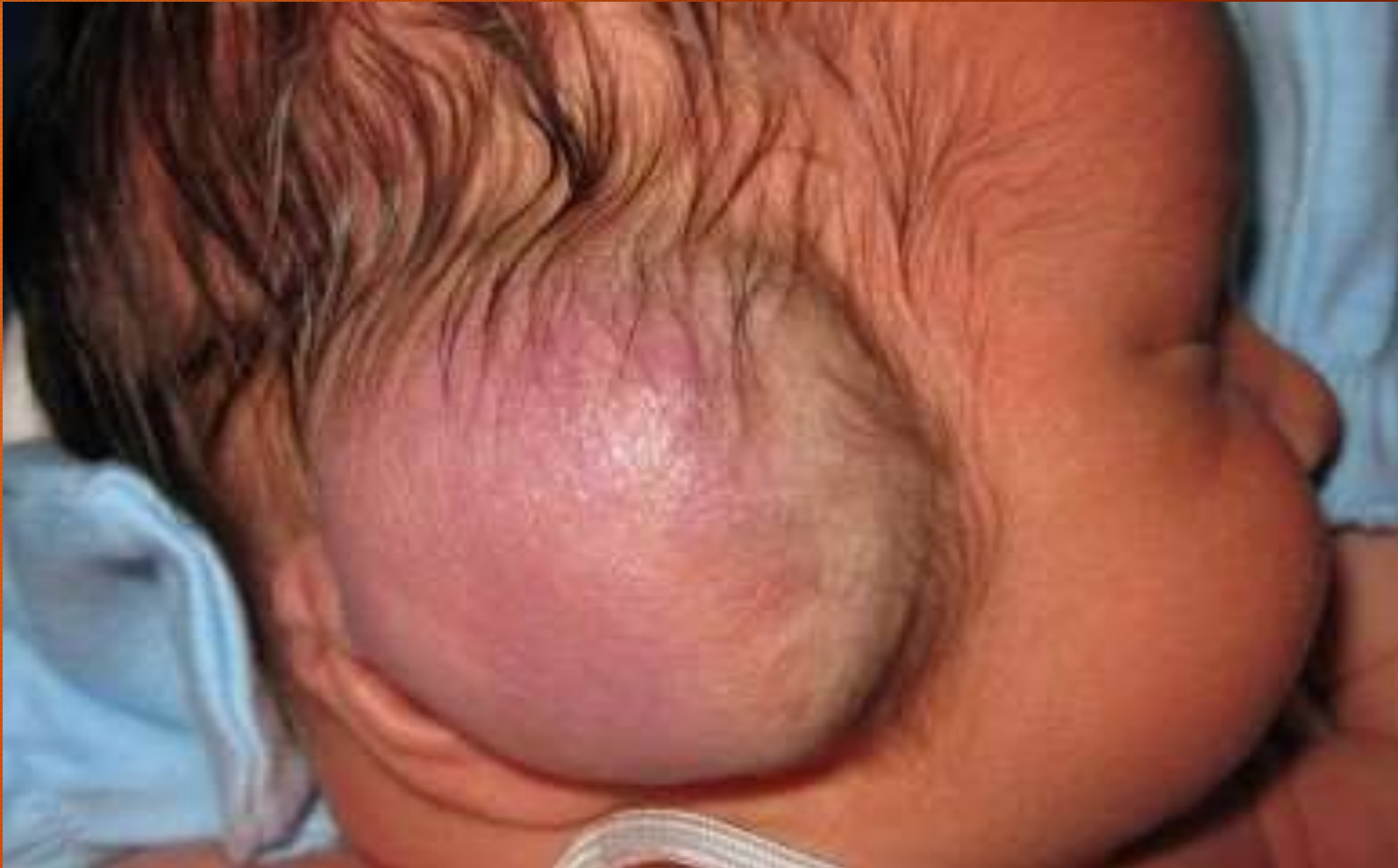



# Ocular Hemangioma - Interfering with Function

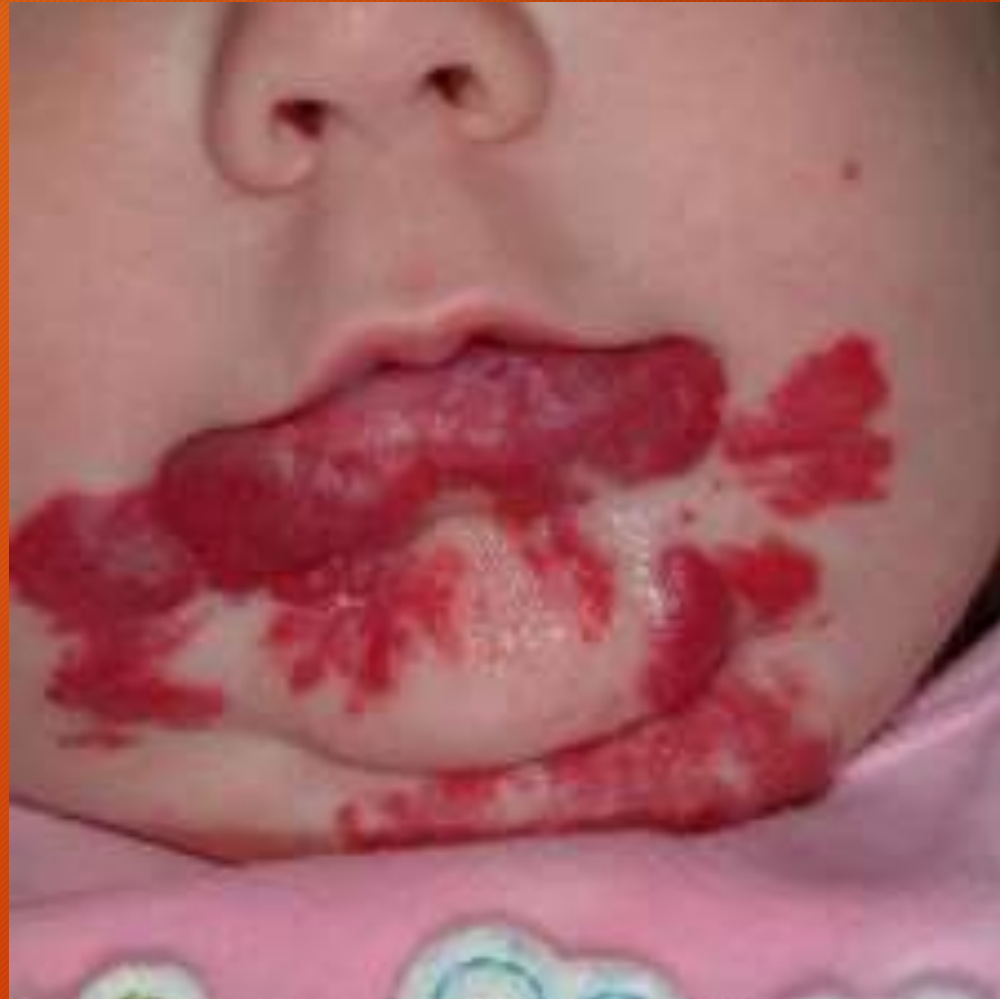

# Large Facial Hemangioma - Interfering with Function

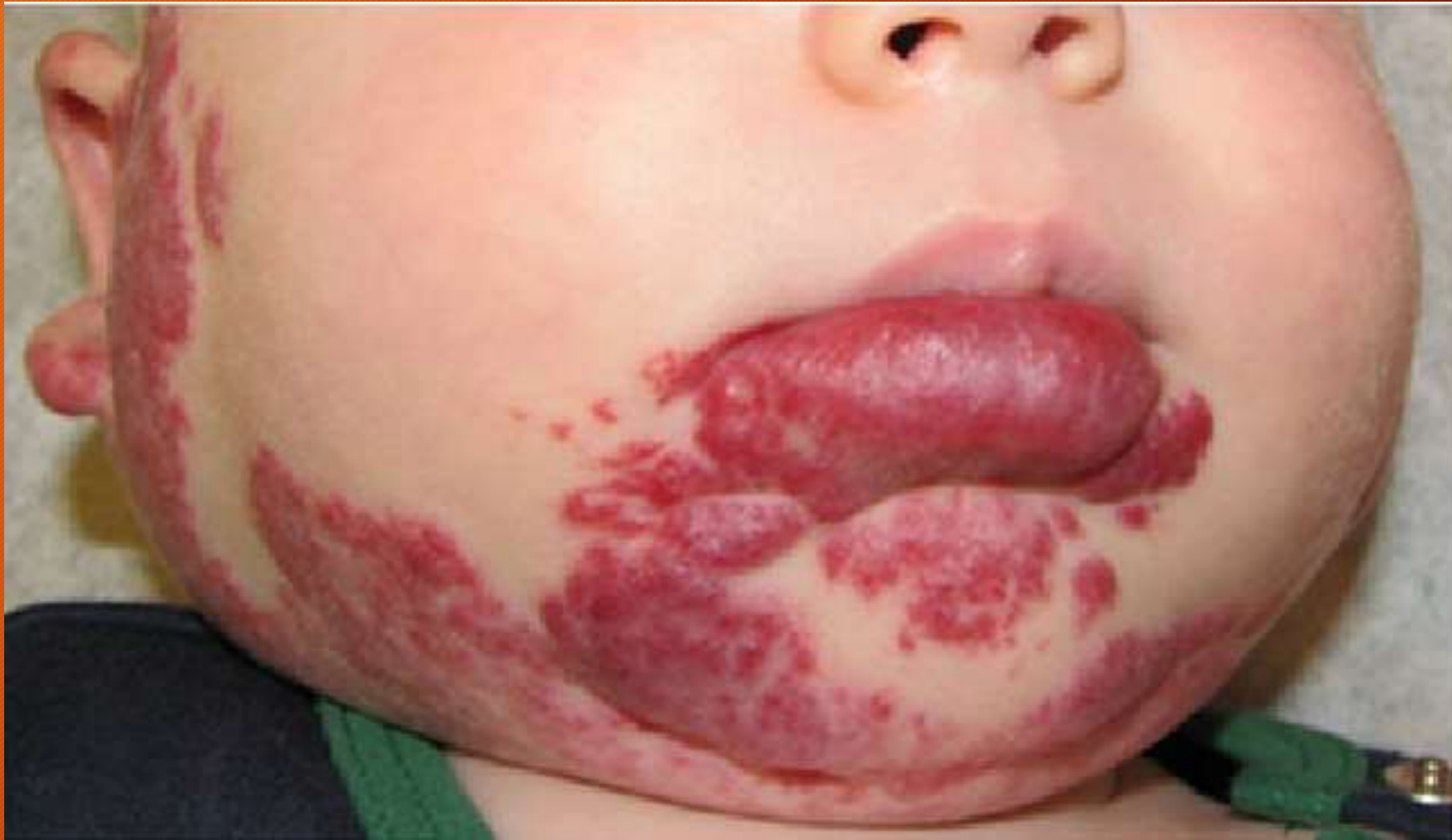

# Lip and Submental Hemangioma

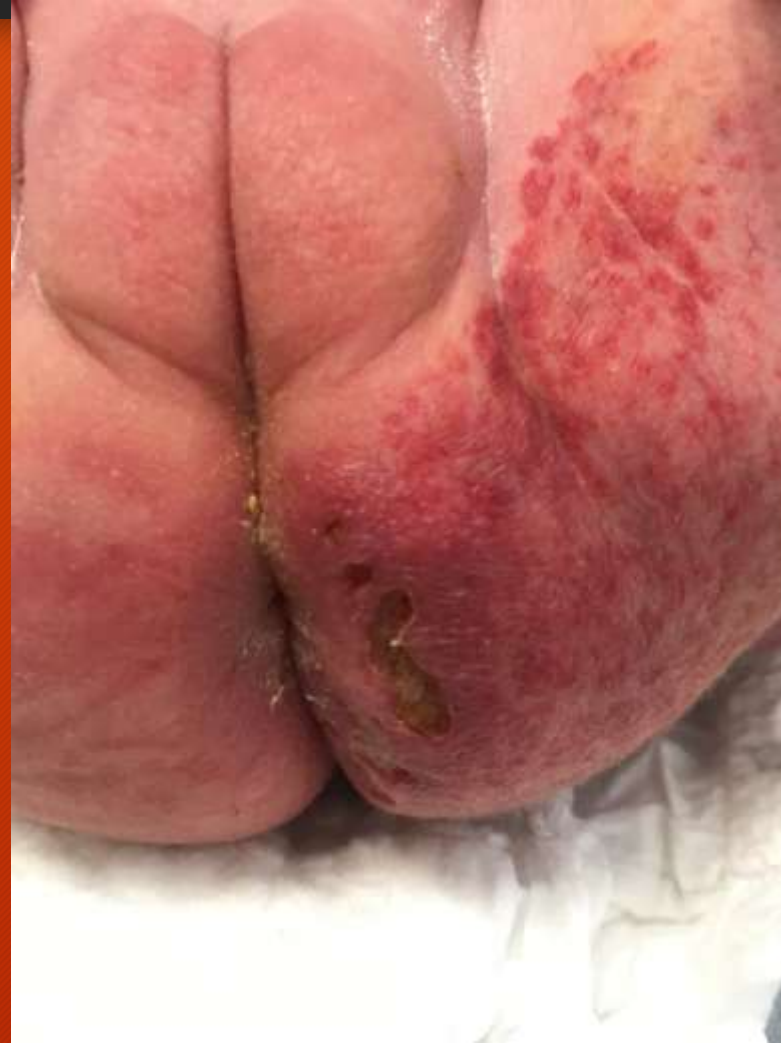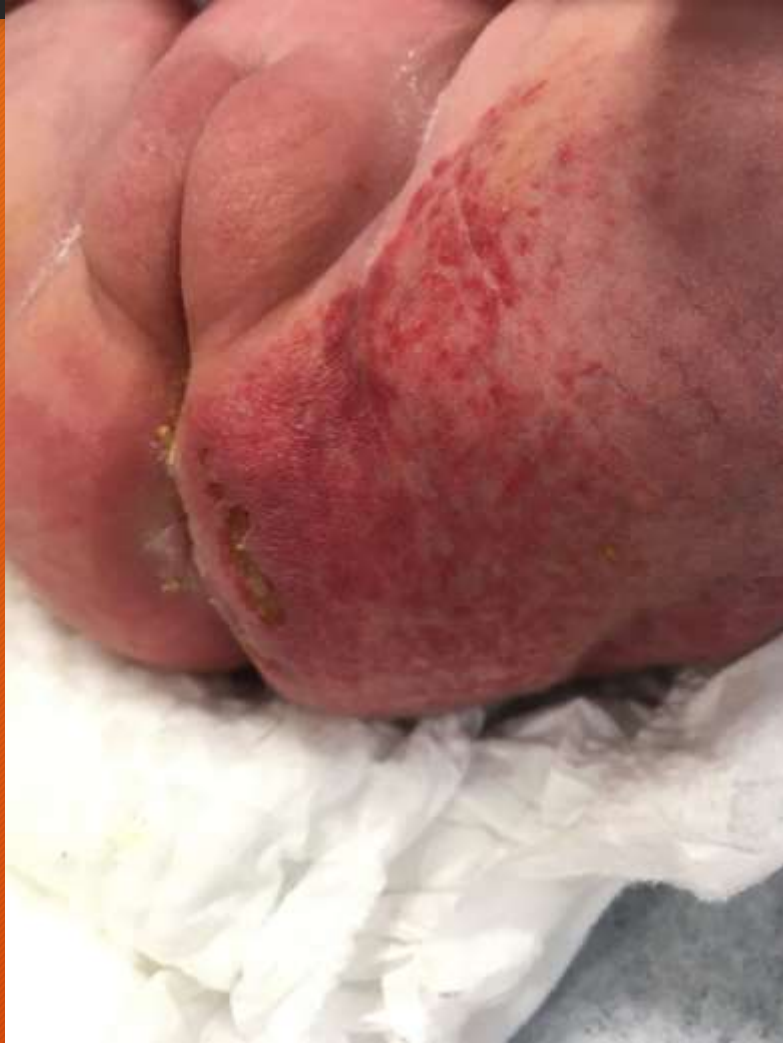## Large Facial Hemangioma



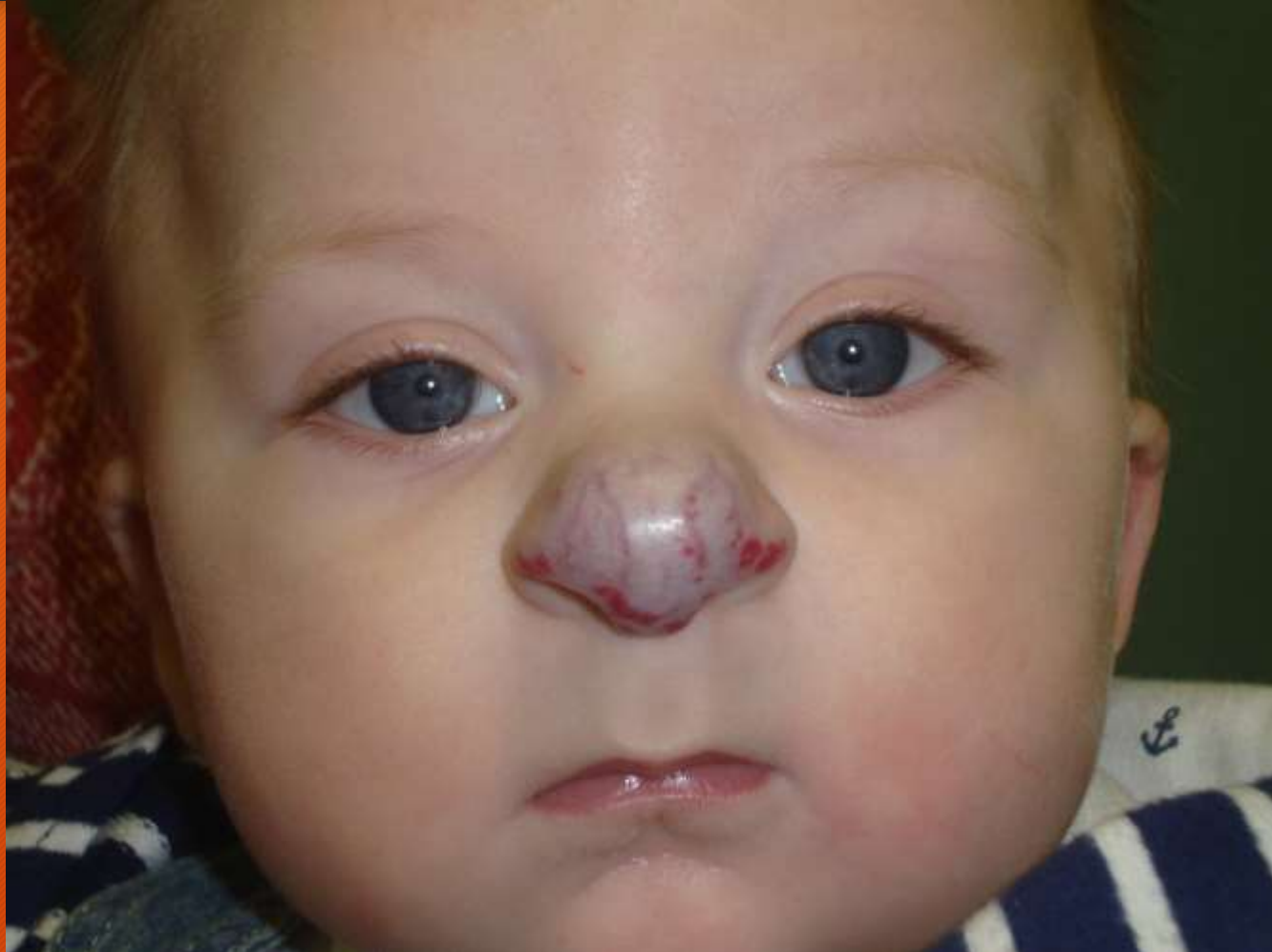# Large Facial Hemangioma



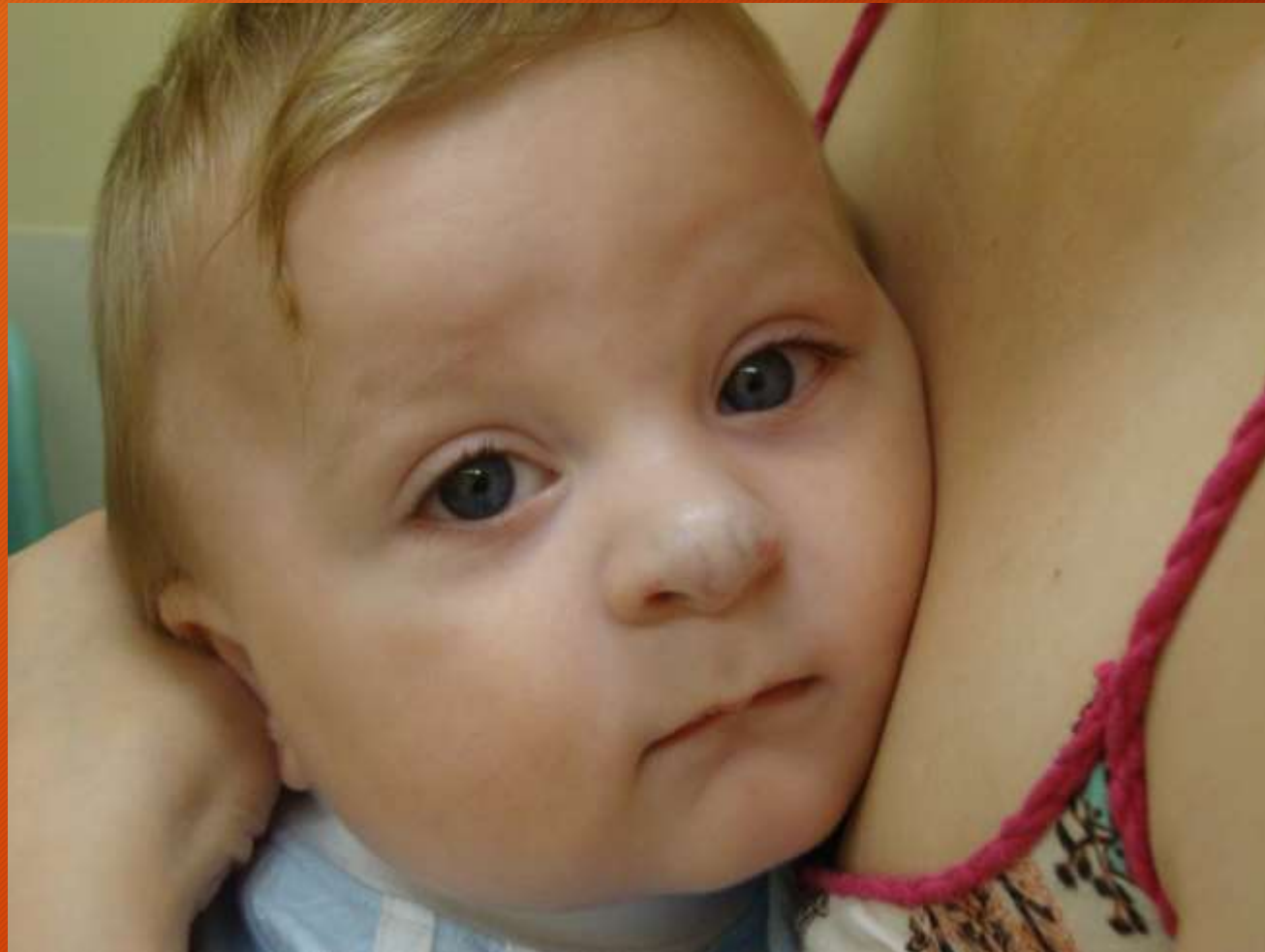# Hemangioma Syndrome - PELVIS, Ulcerated



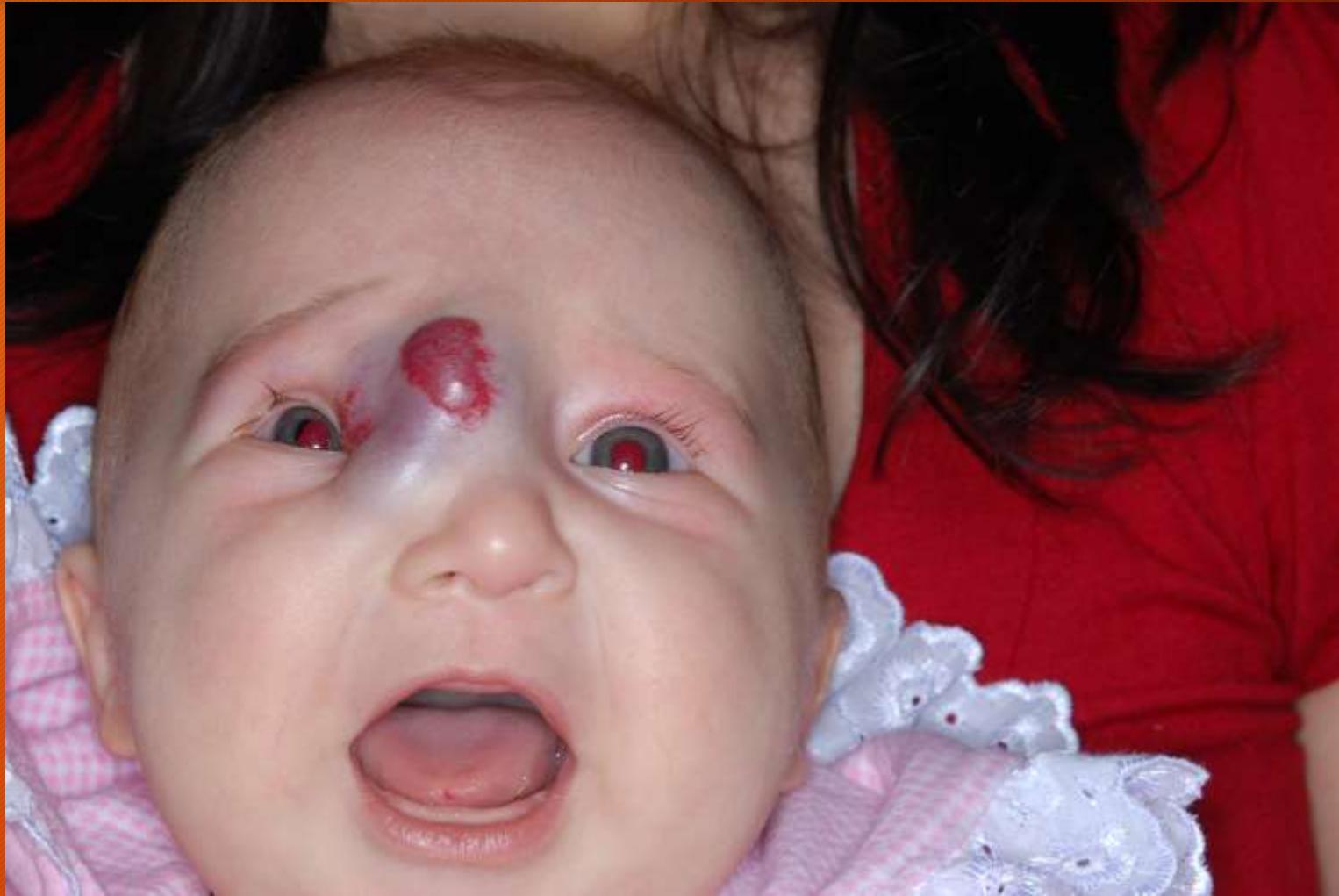# Tip of Nose - Possible Destruction of Cartilage



# On Propranolol - 12 Months of Age

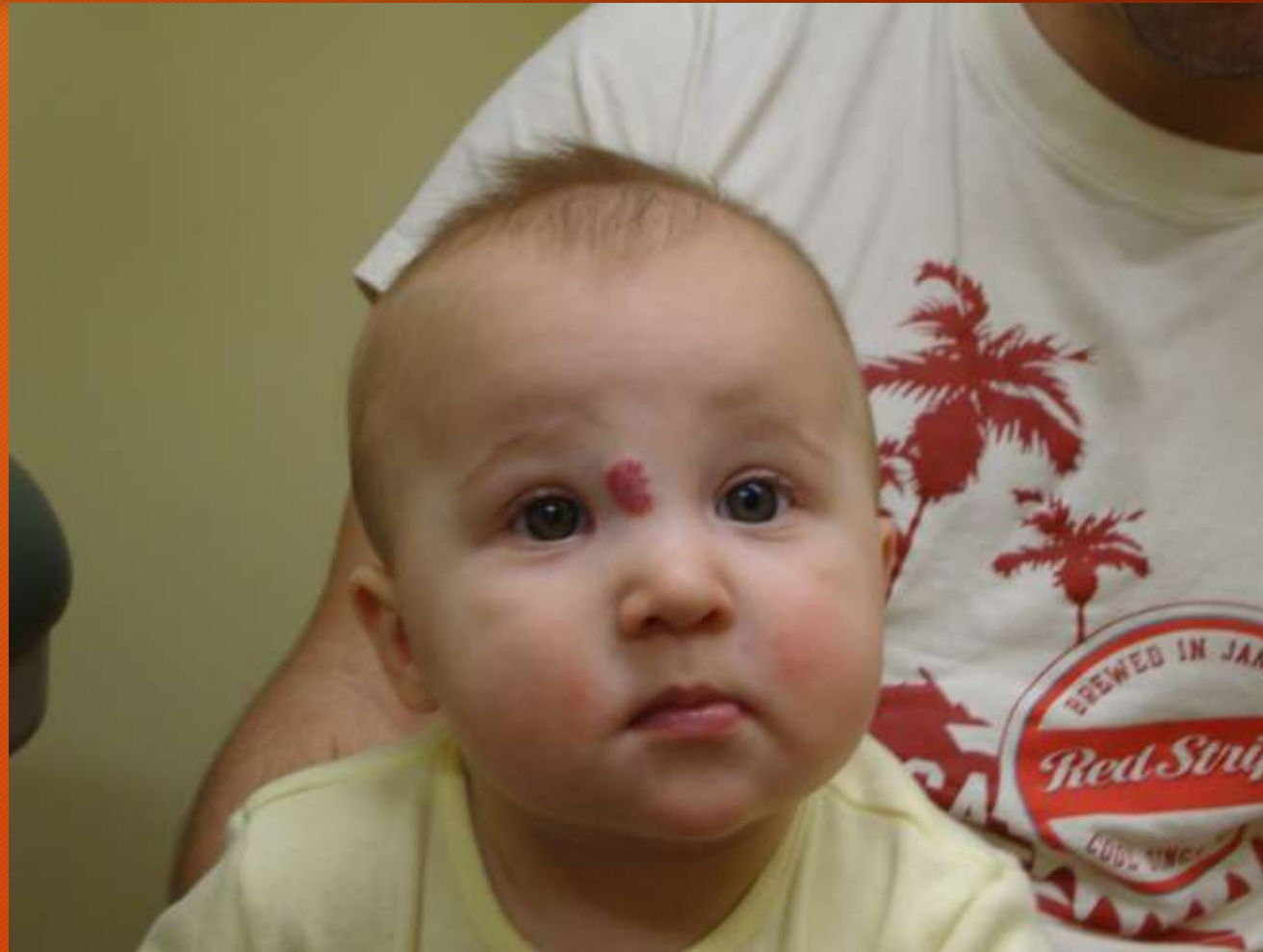

# Ocular Hemangioma - Interfering with Vision





# On Propranolol - 12 Months of Age



# Hemangiomas - Summary

- Propranolol is effective new treatment
- Hemangiomas that require treatment
  - Function threatening - eyes, nose, ears, lips, beard area
  - Ulcerated - lips, folds, perineal, rapidly growing
  - Syndromes - large facial, larger perineal, lower spine, multiple
- Refer early and urgently to pediatrician or dermatologist familiar with treating hemangiomas

# Hypopigmented and Depigmented Lesions - White Lesions

- A more common problem with the changing population
- More of a cosmetic concern for darker skinned races
- In some cultures patients are shunned for white lesions - concern about leprosy

# White Lesions

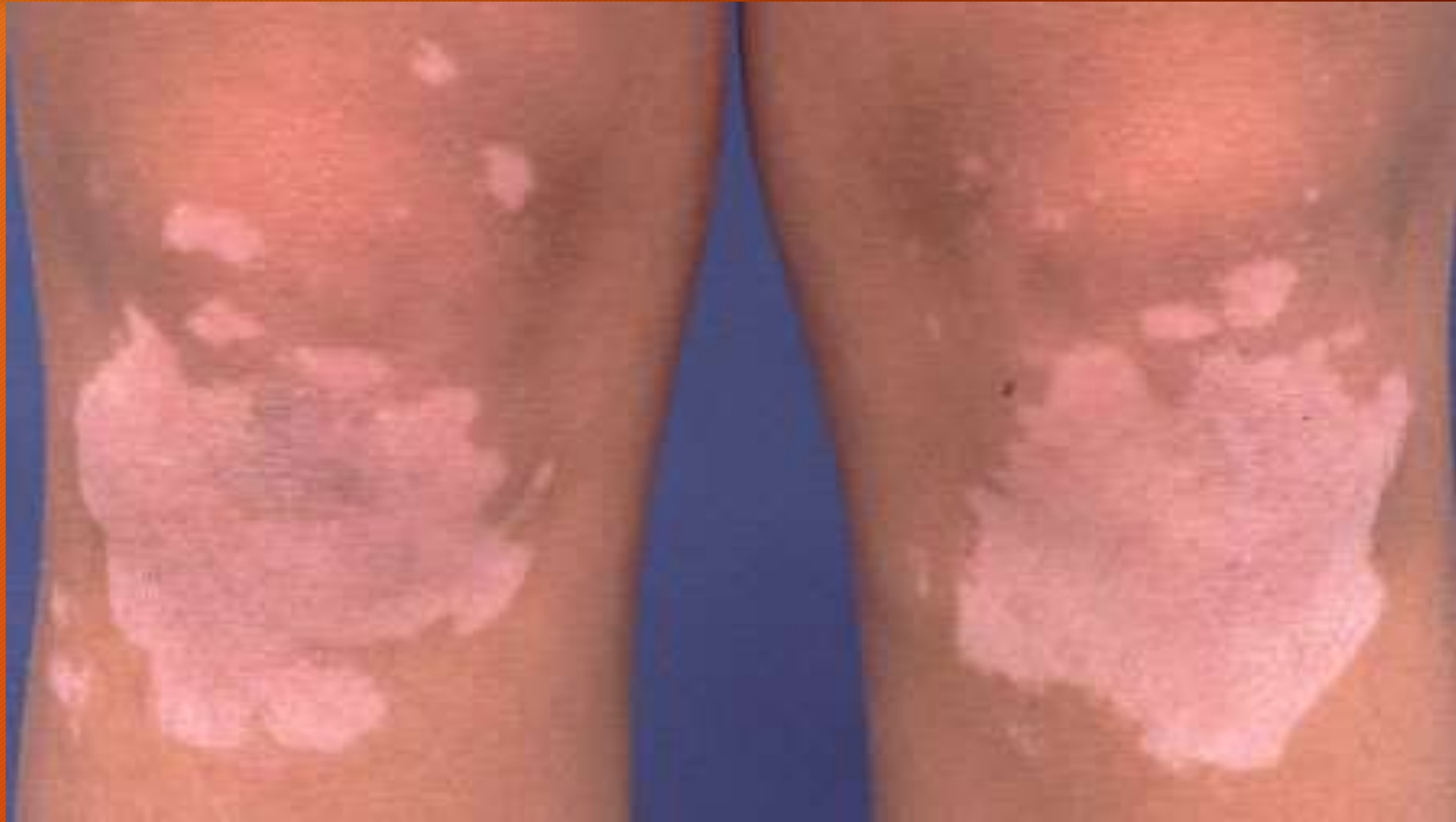- Vitiligo
- Halo nevus
- Pityriasis alba
- Post inflammatory hypopigmentation
- Tinea versicolor
- Nevus Depigmentosus
- Ash leaf spots
- Others - leprosy, hypopigmented mycosis fungoides, discoid lupus, lichen sclerosis, chemical depigmentation

# White Lesions

## Case 1

- 9 yo female with 6 month history of white lesions on her hands, knees and periorbital area
- Gradually spreading
- Asymptomatic
- Grandmother has similar lesions

# Case 1



# Vitiligo

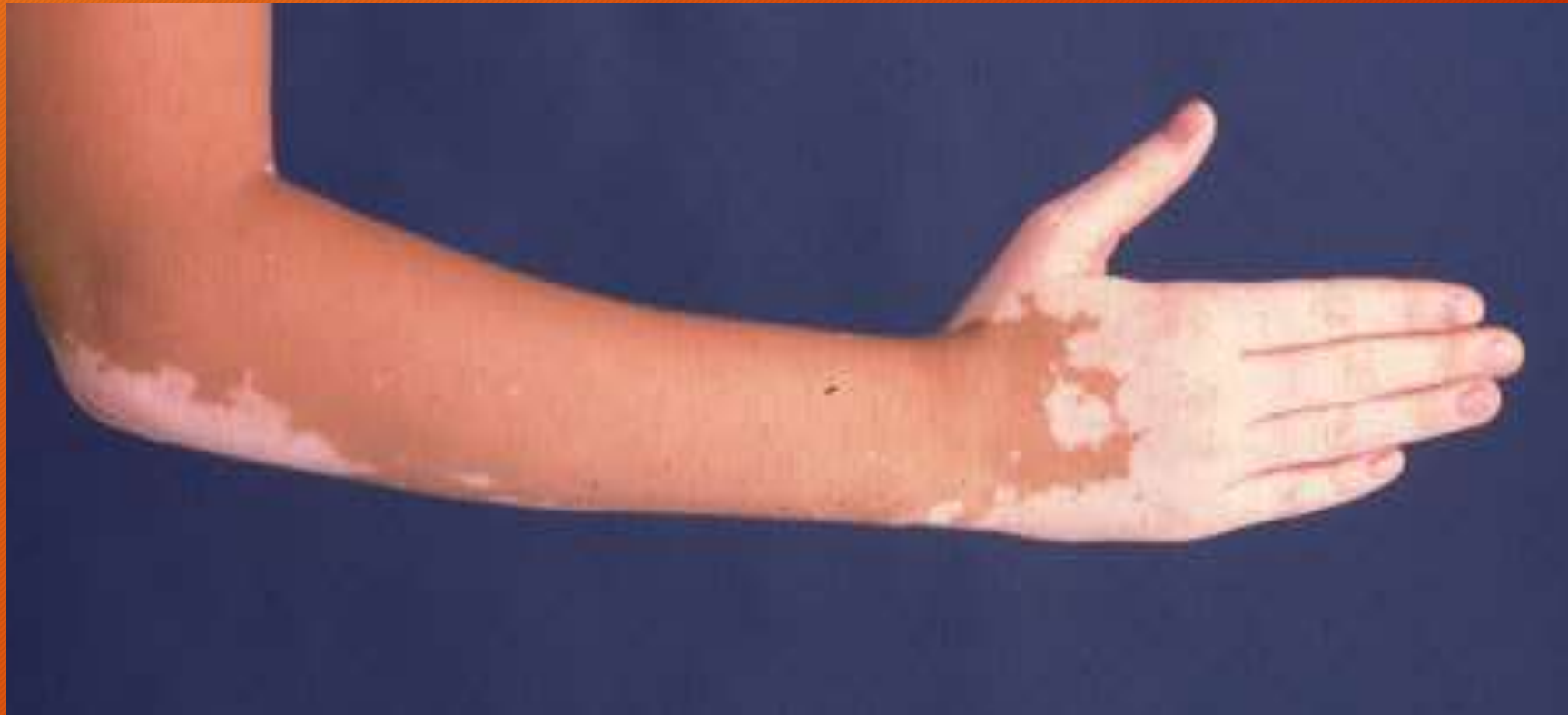- Common - affects 1% of all populations - 8% of East Indians
- Multifactorial inheritance pattern
- Patients are generally healthy but have an increased risk for other autoimmune disorders - thyroid disease, pernicious anemia, diabetes, lupus, RA, psoriasis, alopecia areata
- Acquired depigmenting disorder where melanocytes are destroyed
  - 1. Pigment cells are injured by abnormally functioning nerve cells
  - 2. Autoimmune reaction against pigment cells
  - 3. Auto-toxic theory. Pigment cells self destruct

# Vitiligo - Clinical Features

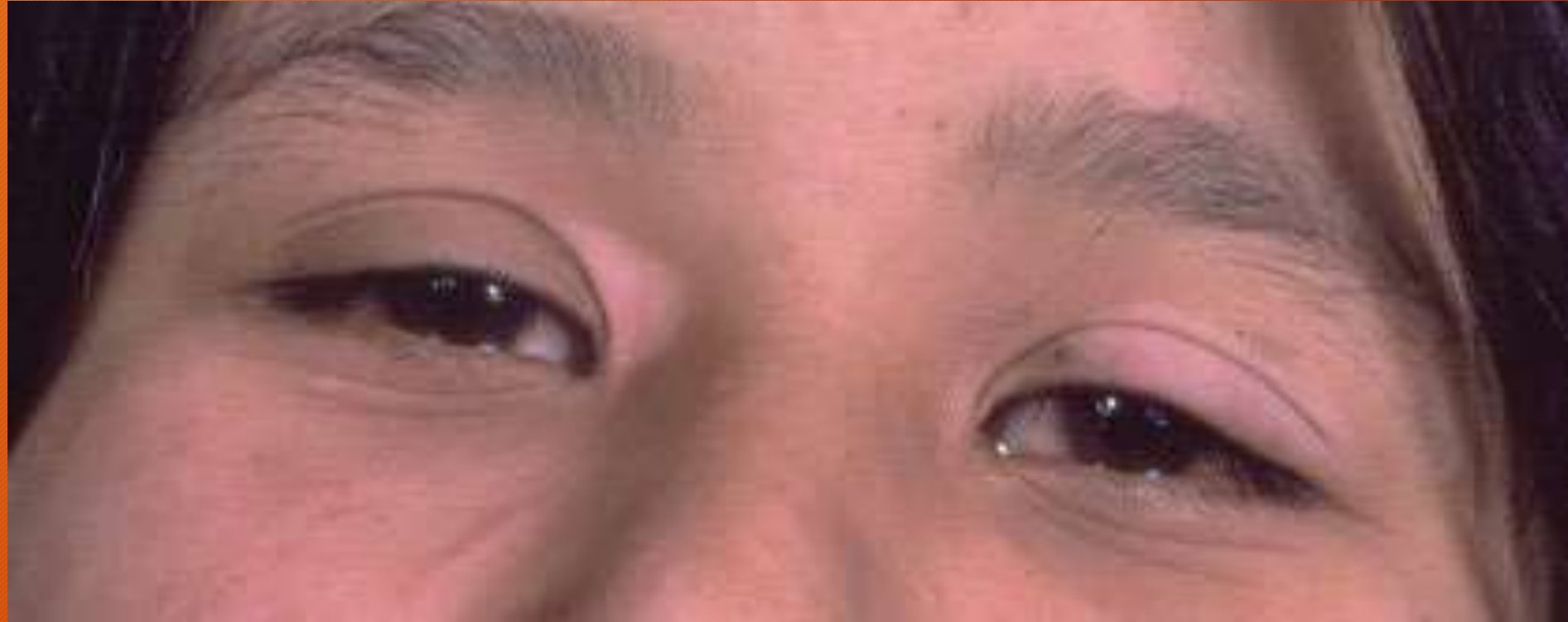- Any part of body but predilection for face, fingertips and toes, folds, genitals, bony prominences and sites of injury
- Complete loss of pigment - may have a hypo or hyperpigmented border
- Sharply demarcated
- Symmetrically distributed
- May be few or many lesions
- Accentuation with Wood's lamp
- Diagnosis is made clinically



# Vitiligo - Fingertips and Bony Prominences



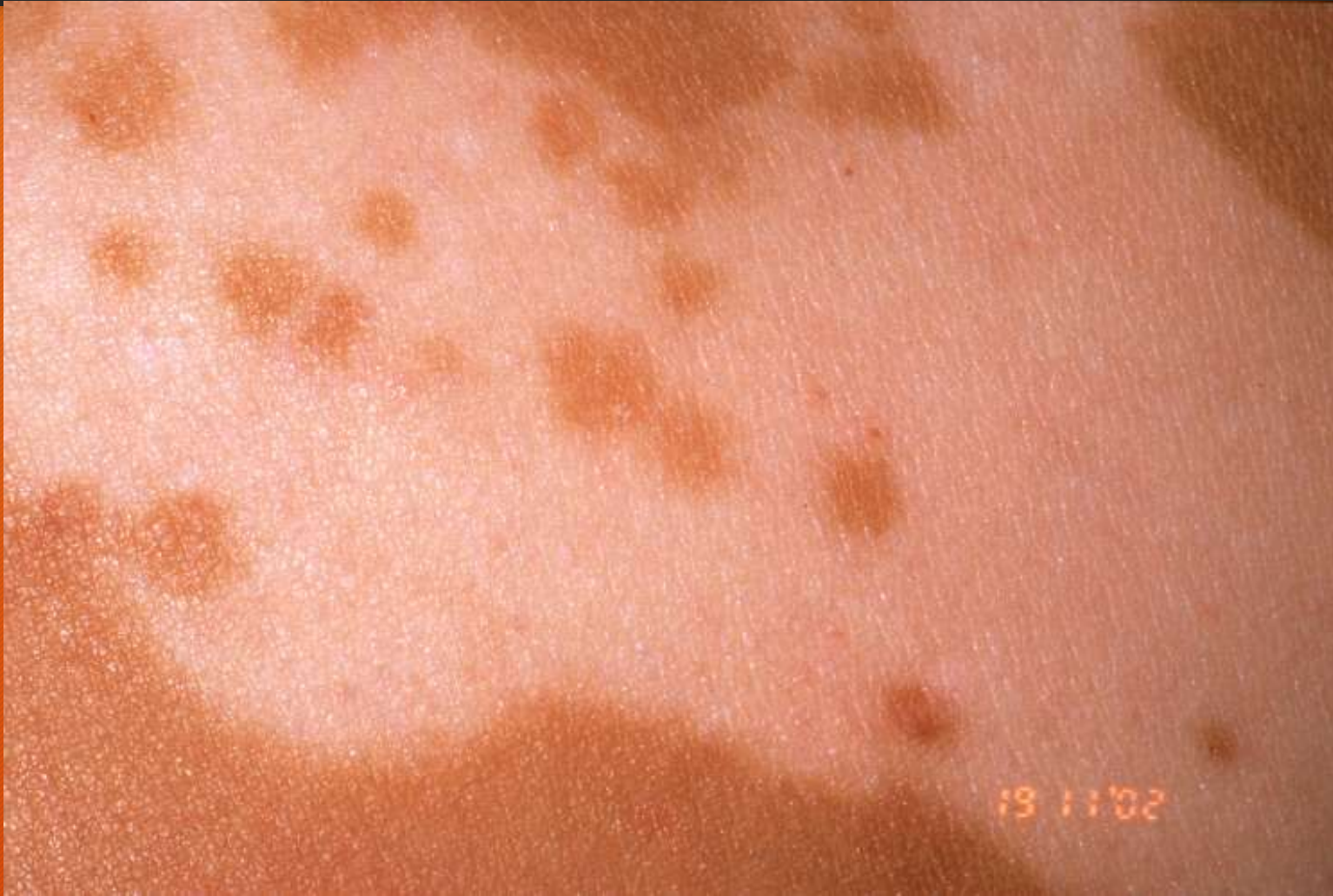# Vitiligo - Periorbital



# Vitiligo - Course

- 50% start before the age of 18
- Course is unpredictable and variable
- Generally periods of pigment loss and periods of stabilization
- May be exacerbated by emotional stress
- Rarely spontaneous repigmentation
- Repigmentation comes from melanocyte stem cells in the hair bulbs - see follicular pigmentation
- Sub Type is segmental vitiligo - appears in childhood, is localized, unilateral and stable

# Vitiligo - Follicular Repigmentation



# Vitiligo - Treatment

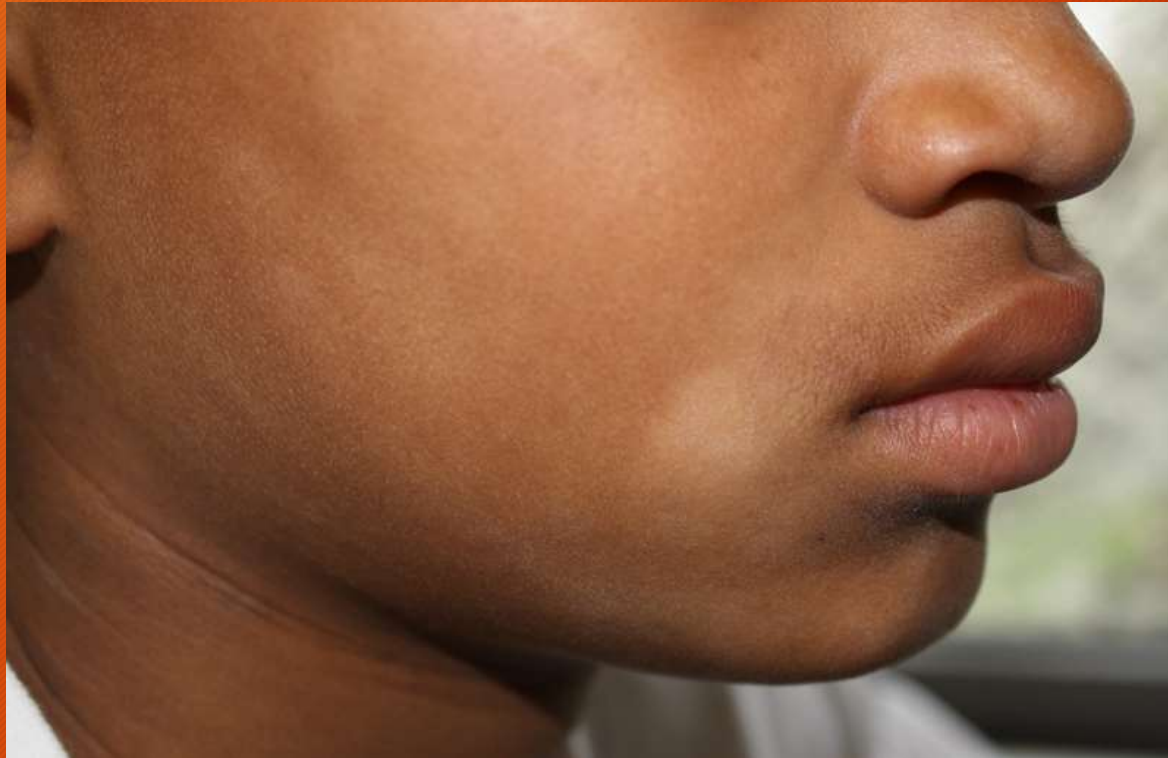- Unsatisfactory
- New lesions are more likely to respond than old lesions
- Facial and truncal lesions are more responsive than hands and feet
- Sun protection
- Camouflage - make up (Cover Fx®, Dermablend®), self tanning lotion, tattooing
- Topical steroids - high potency
- Topical calcineurin inhibitors - Tacrolimus .1% for face and folds
- Phototherapy - NBUVB, PUVA
- New treatments - JAK inhibitors, Ruxolitinib, monoclonal Ab's

# White Lesions

## Case 2

- 10 yo male with white spots on cheeks since July
- Has been fading a bit since the summer ended
- Asymptomatic
- He does have a history of eczema as a baby

## Case 2



# Pityriasis Alba

- Post inflammatory hypopigmentation secondary to eczema
- More noticeable with darker skin tones
- Worse in the summer months due to tanning of the surrounding skin
- Erythema and scaling may be more noticeable in the winter



# Pityriasis Alba - Clinical Features

- Most common on the face (cheeks and chin), neck, shoulders and upper arms
- Round or oval or irregular in shape
- Edges are generally ill defined
- Hypopigmented patches with slight scale
- Some may be pink but are lighter than the surrounding skin
- 0.5 to 5 cms in size
- Does not enhance with Wood's lamp

# Pityriasis Alba - Treatment

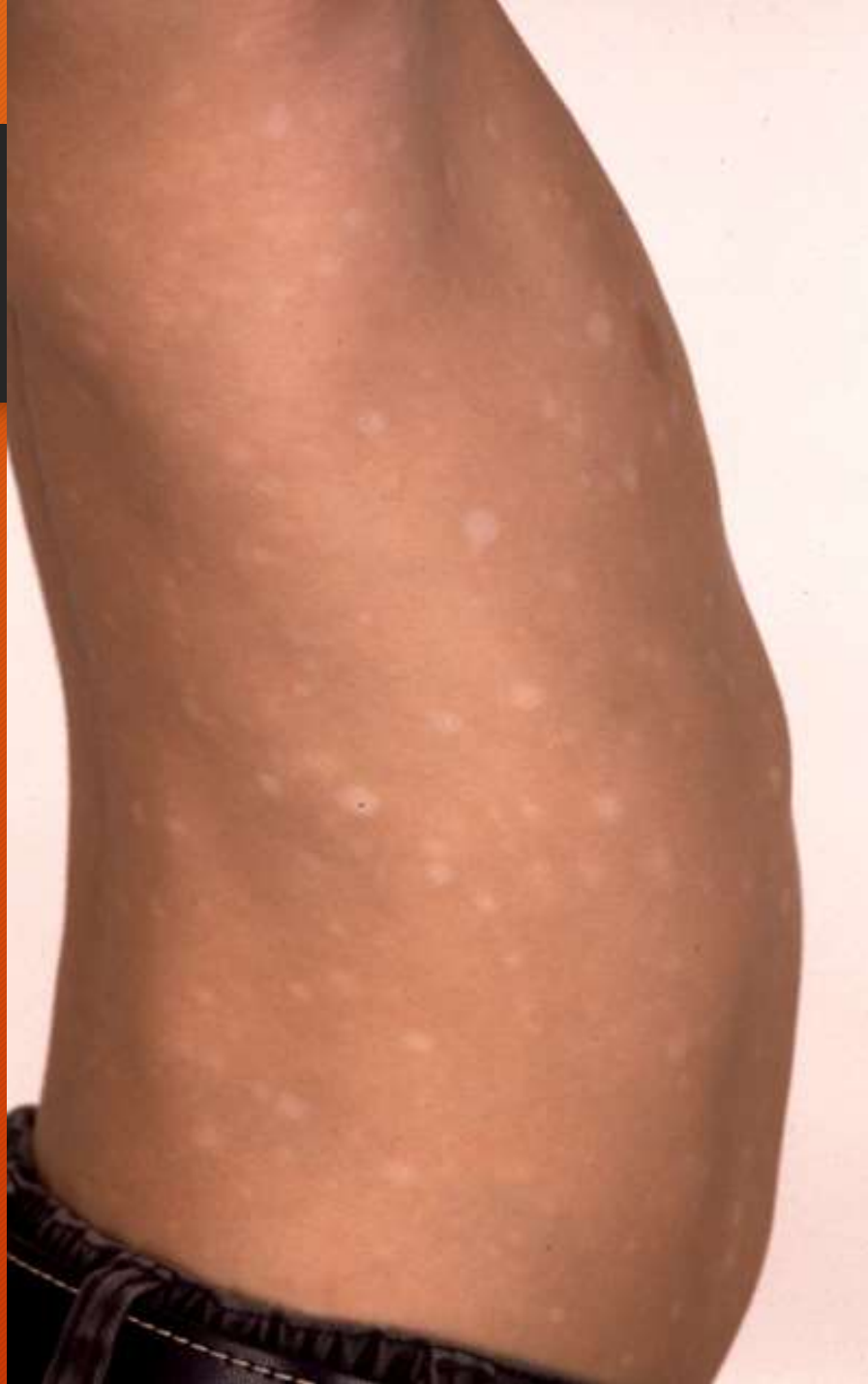- Mild topical steroid if red or scaly
- Topical calcineurin inhibitors
- Sunscreen to reduce contrast
- Moisturizers to prevent recurrence
- Usually resolves after a few months - over the winter
- Some cases persist for 2 - 3 years
- Color gradually returns to normal

# White Lesions

## Case 3

- 10 yo male with numerous white spots on his trunk for 2 months
- Previously there were red scaly bumps but these have all disappeared
- He has been well but did have a Strep throat several months ago

# Case 3



# Post Inflammatory Hypopigmentation

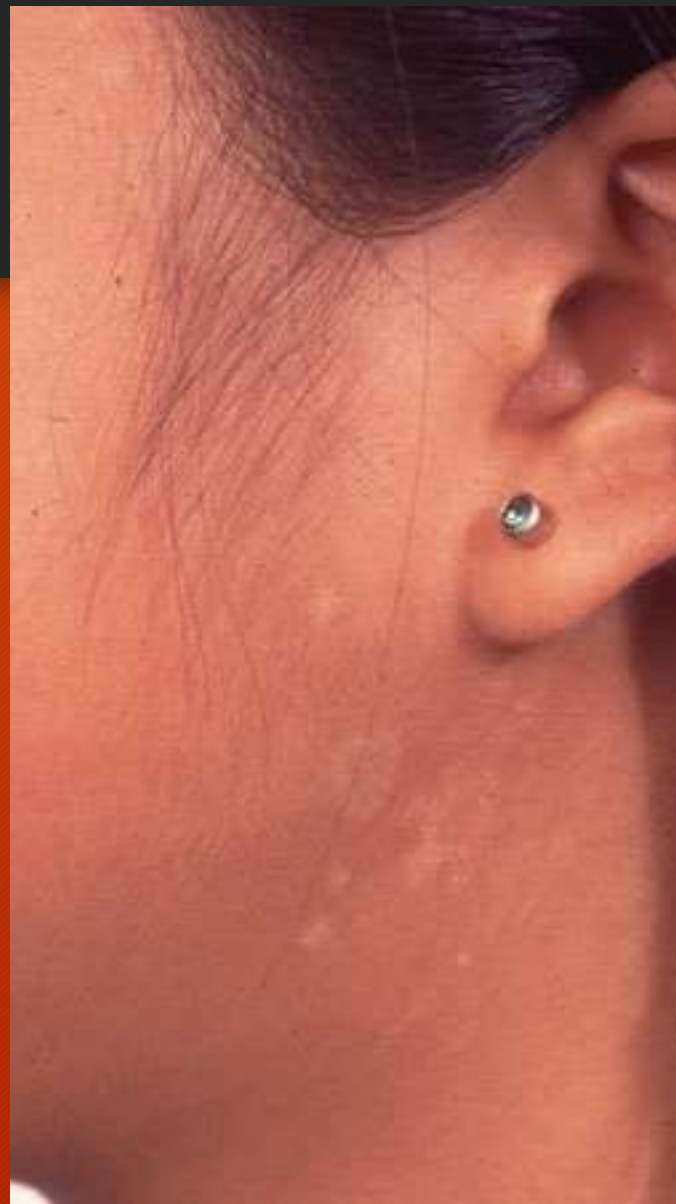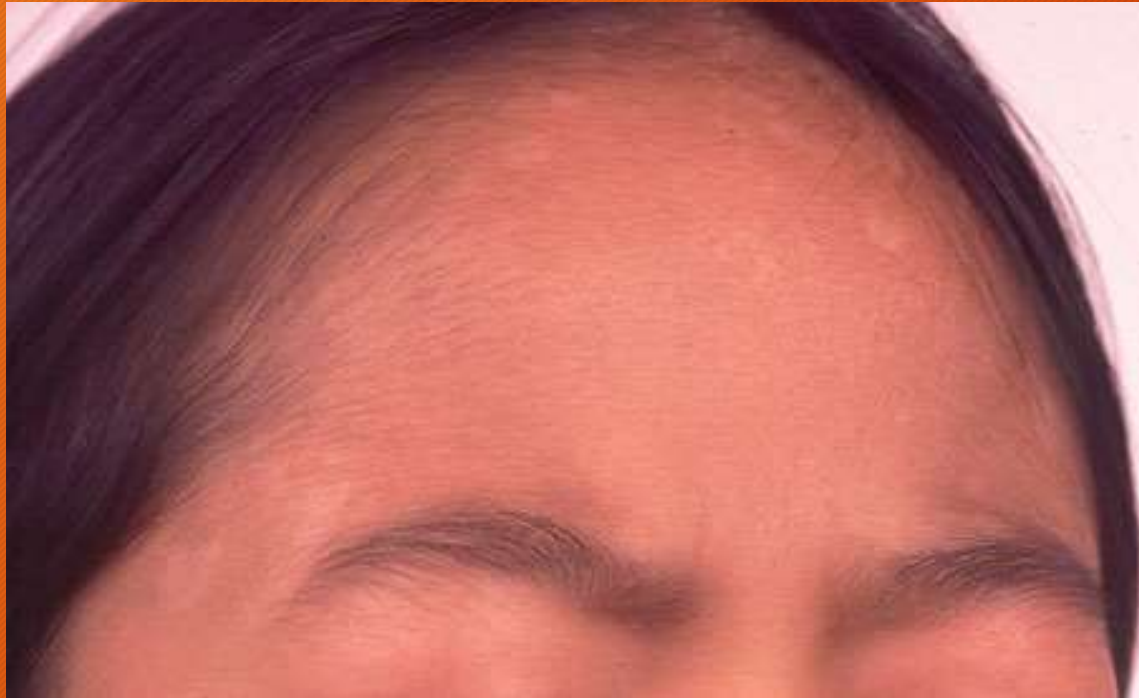- Caused by different types of inflammation - usually a history of a preceding rash
- Lesions are hypopigmented not depigmented
- Borders are generally ill defined
- Does not enhance with the Wood's lamp
- Treat the underlying condition
- White spots resolve with time

# White Lesions

## Case 4

- 14 yo female with white spots on face, neck and upper back since July
- Asymptomatic
- Older sister has similar lesions
- No air conditioning at home

# Case 4



# Tinea Versicolor (Pityriasis Versicolor)

- Caused by a yeast - *Malassezia furfur* - a normal inhabitant of the skin - becomes hyphal form
- *Malassezia furfur* produces azelaic acid which is a tyrosinase inhibitor
- More common in warm, moist climates or with increased perspiration
- Also seen with immunosuppression and in some with a hereditary predisposition
- Most common in young adults but can be seen in children, infants and the elderly



# Tinea Versicolor

- Well defined papules which coalesce into plaques
- May be coppery brown, pink or hypopigmented
- Fine scale can be seen
- Asymptomatic or slightly itchy
- Most common on the upper trunk, neck, proximal extremities and face (along the hairline)
- Scraping for KOH examination shows spores and hyphae (spaghetti and meatballs)
- Wood's lamp shows a yellow green fluorescence
- Cannot be cultured

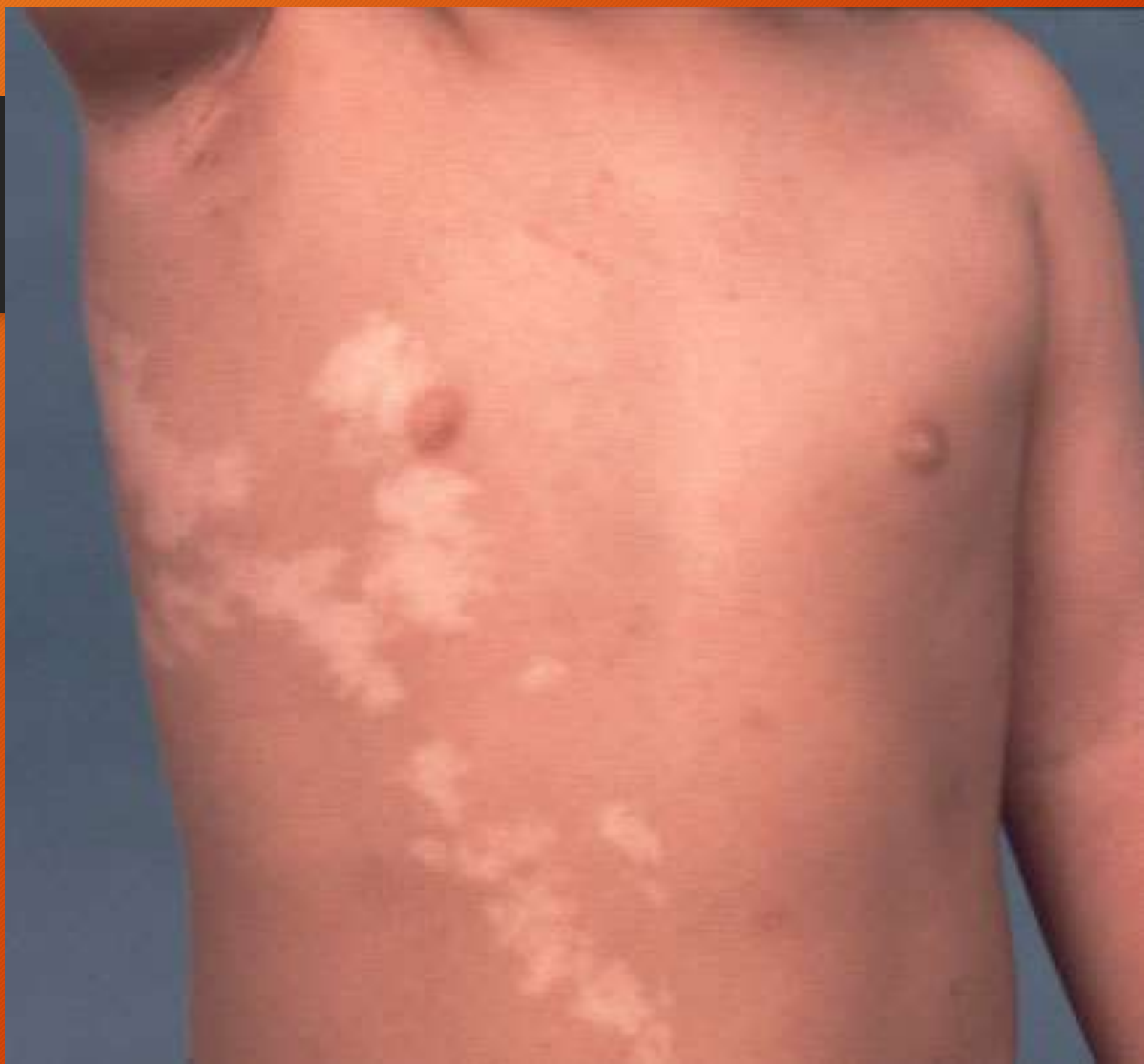# Tinea Versicolor - Treatment

- Topical antifungal creams for 1 - 4 weeks - Clotrimazole, Ketoconazole, Terbenafine, Ciclopirox etc.
- Shampoos with selenium sulfide (Selsun Blue) or zinc pyrethrin (Head and Shoulders) or ketoconazole (Nizoral) left on overnight for several days
- Oral Itraconazole 200 mg OD for 1 - 2 weeks if extensive
- If recurrent use antifungal shampoo as a body wash once a week
- Hypopigmentation may take many months to resolve
- Once treated, sun exposure may stimulate re-pigmentation

# White Lesions

## Case 5

- 11 yo male with white lesions on rt. side of chest and abdomen since 2 years of age
- Has not changed and is asymptomatic
- Otherwise healthy



# Nevus Depigmentosus

- Present at birth or shortly after
- Functional defect of the melanocytes - altered clone of melanocytes
- Lesion is static but grows in proportion to the patient
- Asymptomatic
- White lesions with well defined but irregular borders
- Does not cross the midline
- Usually on the trunk or extremities

# Nevus Depigmentosus



# Nevus Depigmentosus

- **Localized**
  - Most common, single lesion with serrated border
- **Segmental**
  - Larger in size with sharp midline demarcation
  - Usually unilateral streak or patch following Blaschko's lines
- **Linear/ whorled/systematized type**
  - May be extensive, multiple areas
  - Rare
  - May have other systemic symptoms such as seizures, developmental delay and hemi hypertrophy

# Nevus Depigmentosus

- Clinical diagnosis
- Wood's lamp examination shows an off white color
- No specific treatment
- Camouflage could be used or tattooing
- Need sunscreen protection
- No change throughout life

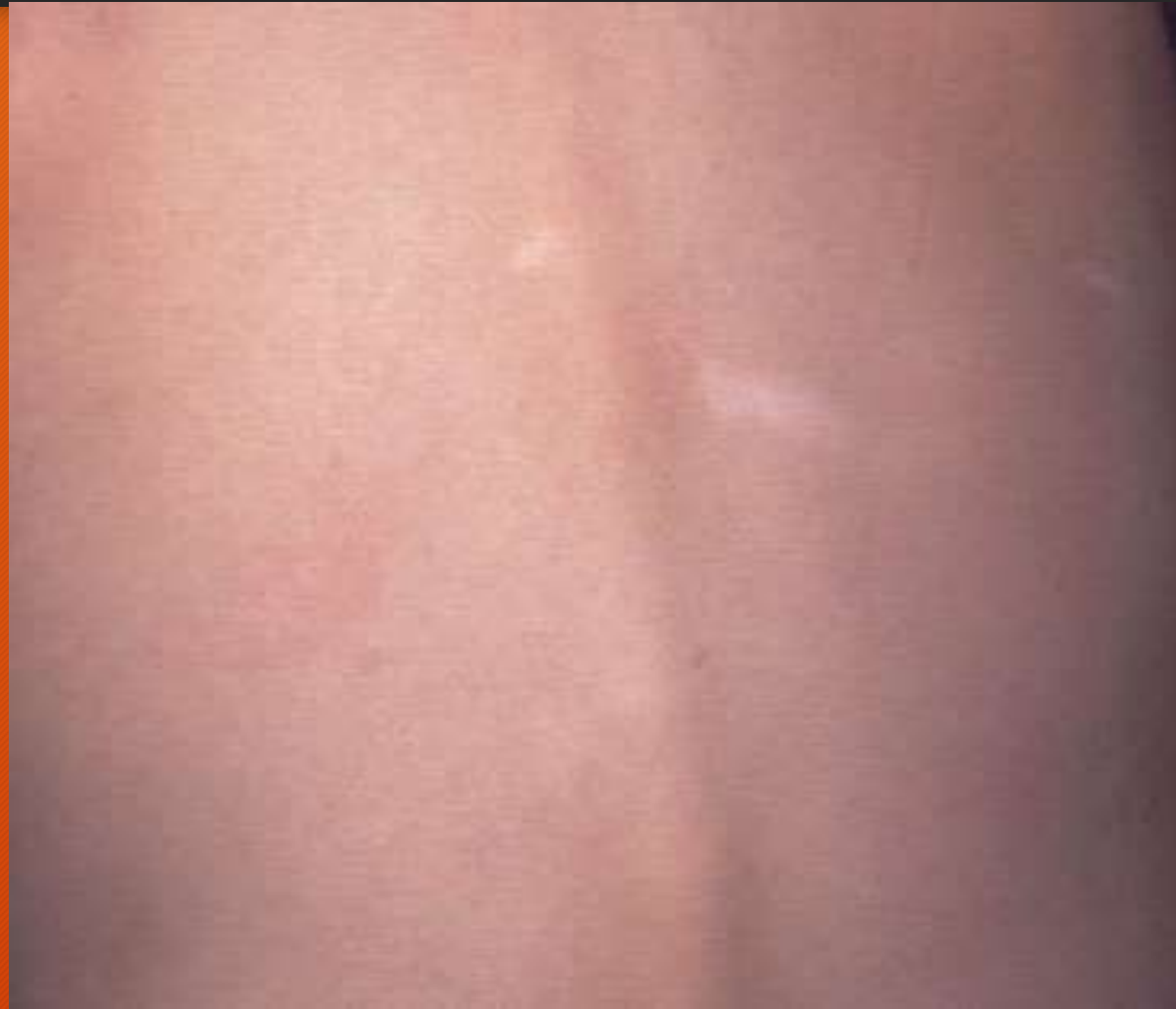

# White Lesions

## Case 6

- 8 yo male with several white lesions on back since infancy
- Otherwise well
- One brother has a seizure disorder and is developmentally delayed

# White Lesions - Case 6



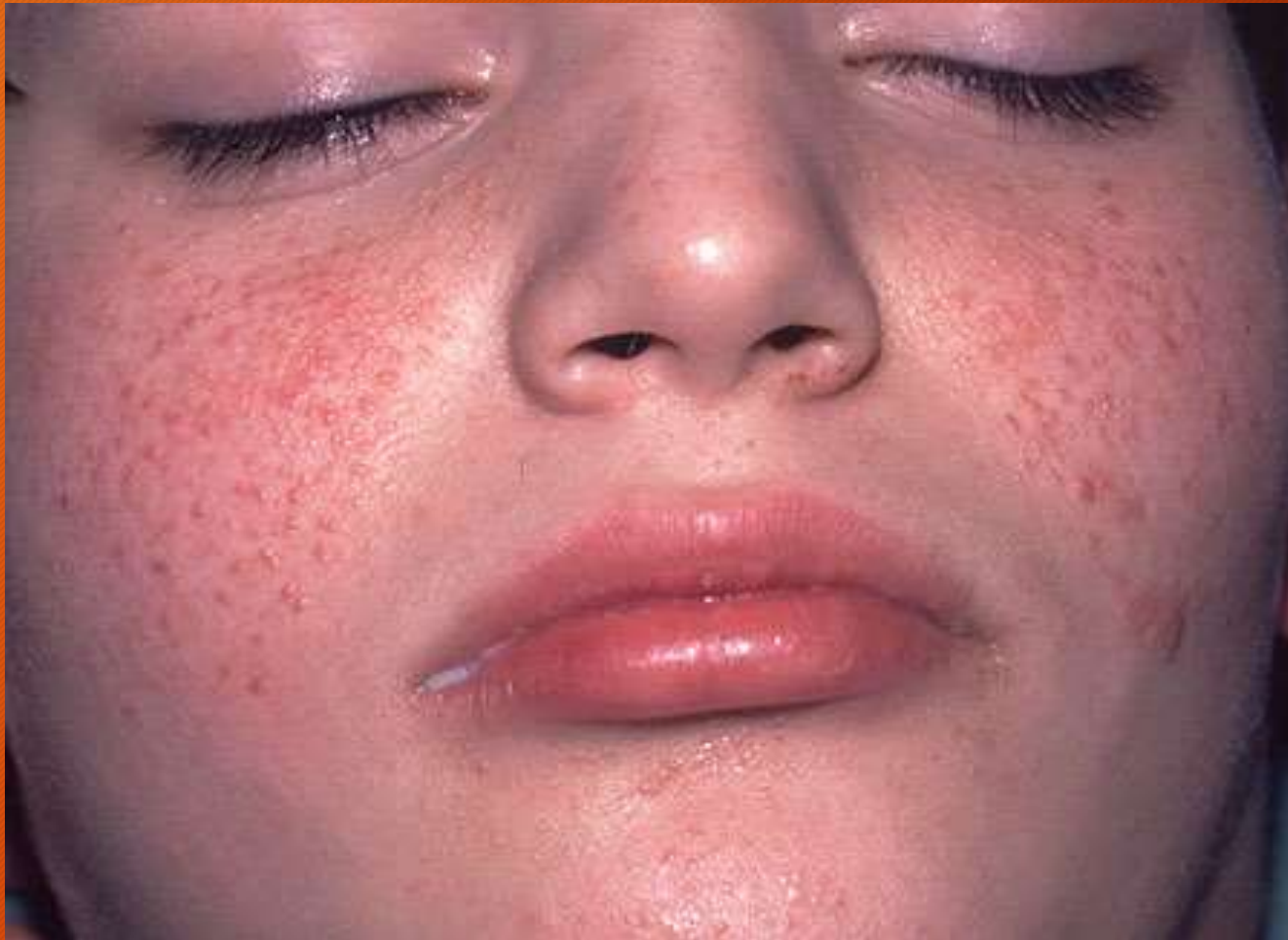# Ash Leaf Spots - Tuberos Sclerosis

- Often the first sign of tuberous sclerosis
- Present in 2/3 at birth
- Occurs in 90% of patients with TS
- Lesions are shaped like an ash leaf - oval with one end round and one end pointed
- May have one or many on the trunk and extremities
- Usually 1 - 3 cms
- Dull white color which highlights with the Wood's lamp

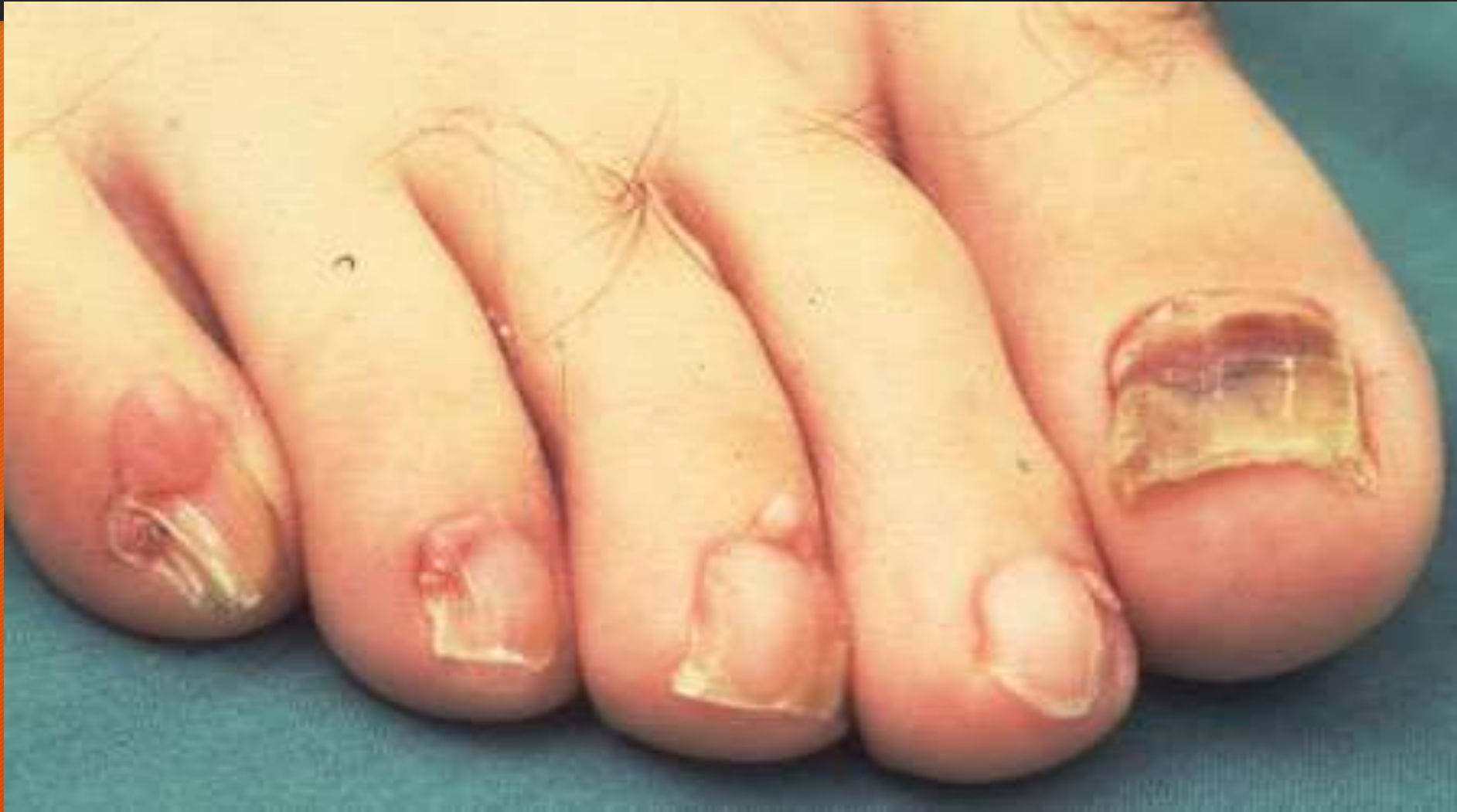# Tuberous Sclerosis

- Need other manifestations of the disease to make a diagnosis - classic triad:
  - Developmental delay
  - Seizures
  - Adenoma sebaceum
- Other characteristic skin changes
  - Adenoma sebaceum - angiofibromas
  - Periungual fibromas
  - Shagreen patch - collagenomas
  - Ash leaf spots

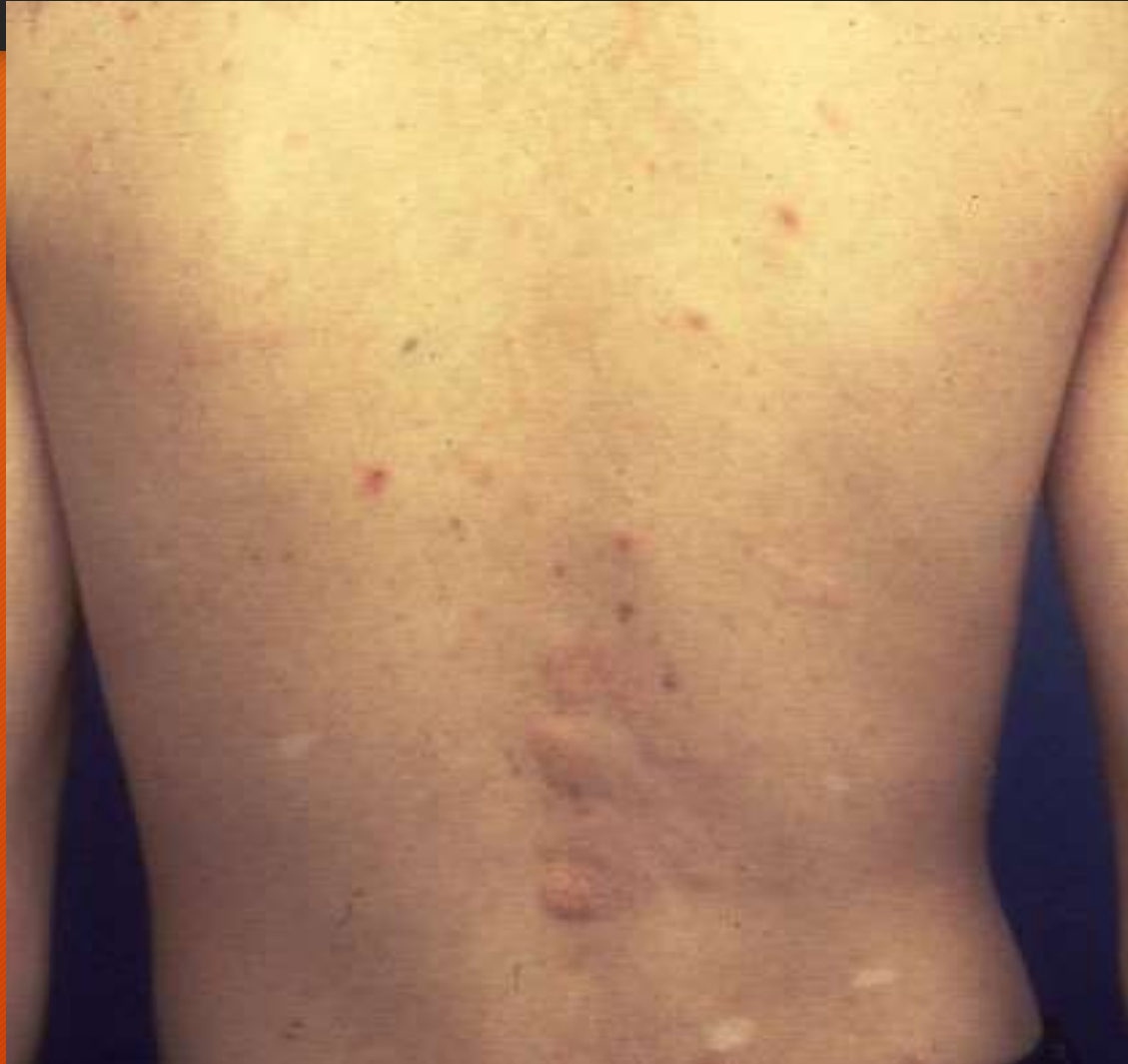# Adenoma Sebaceum - Angiofibromas



# Periungual Fibromas



# Shagreen Patch - Collagenomas

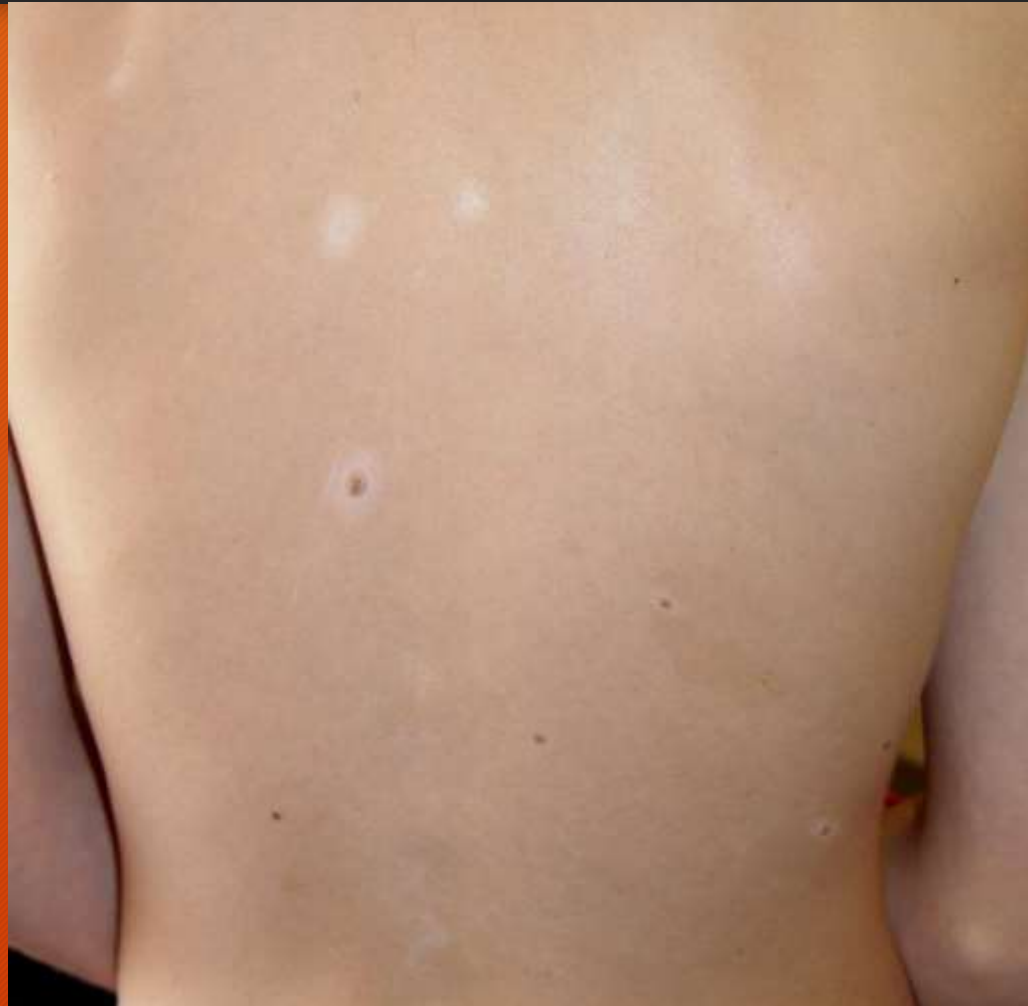

# Case 7

- 15 yo male
- Had a burn on his back during the summer
- Now has several white lesions on his back
- All surround a mole



# Case 7



# Halo Nevi

- Usually seen in children and young adults
- Central mole surrounded by a white halo
- Generally benign
- Asymptomatic
- Usually on the back or trunk
- Sometimes after a burn
- Can be seen with normal nevi and occasionally with melanoma

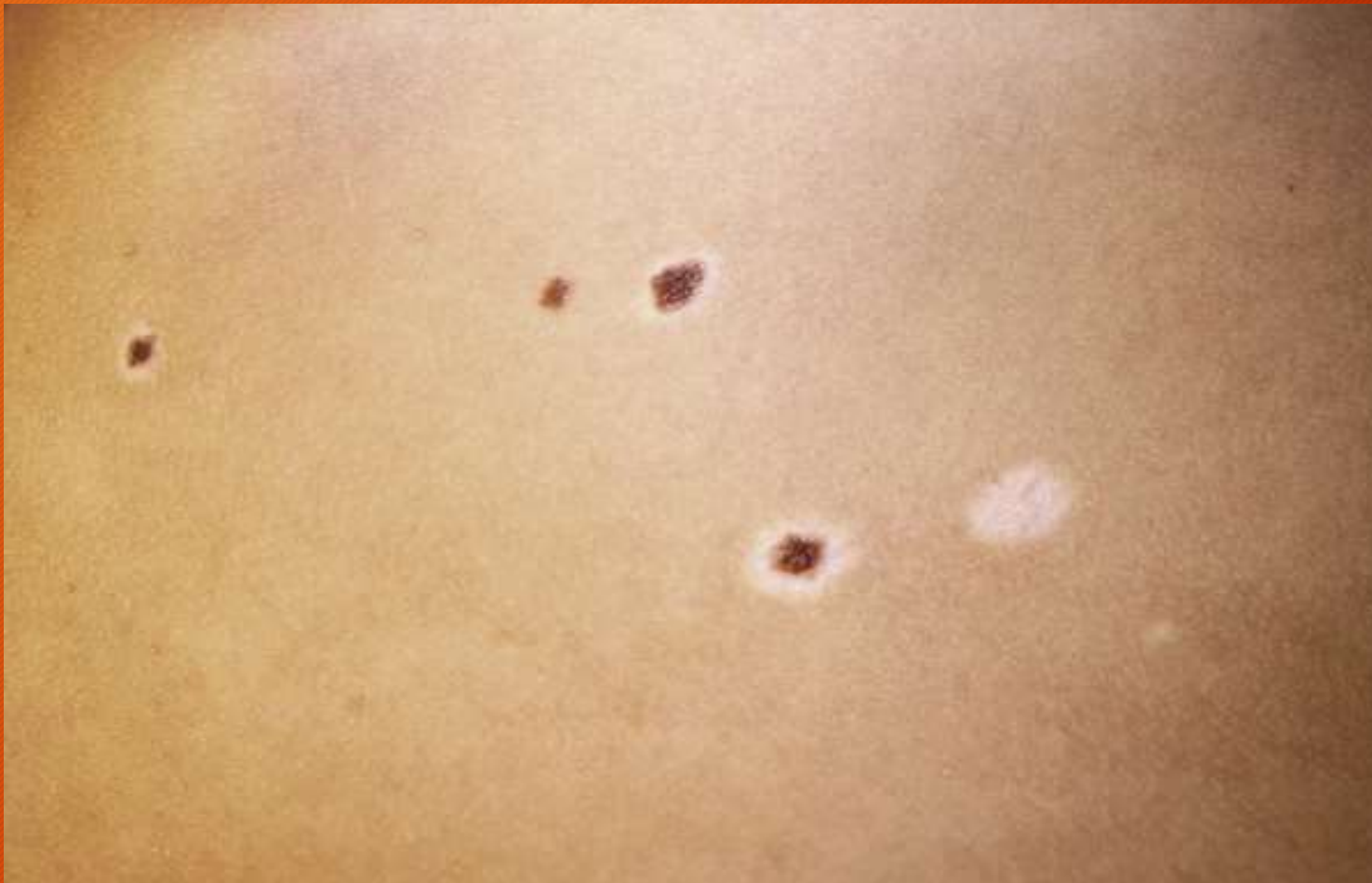
# Halo Nevi - Stages

- Halo
- Loss of color of the central nevus
- Loss of the central nevus
- Loss of the halo

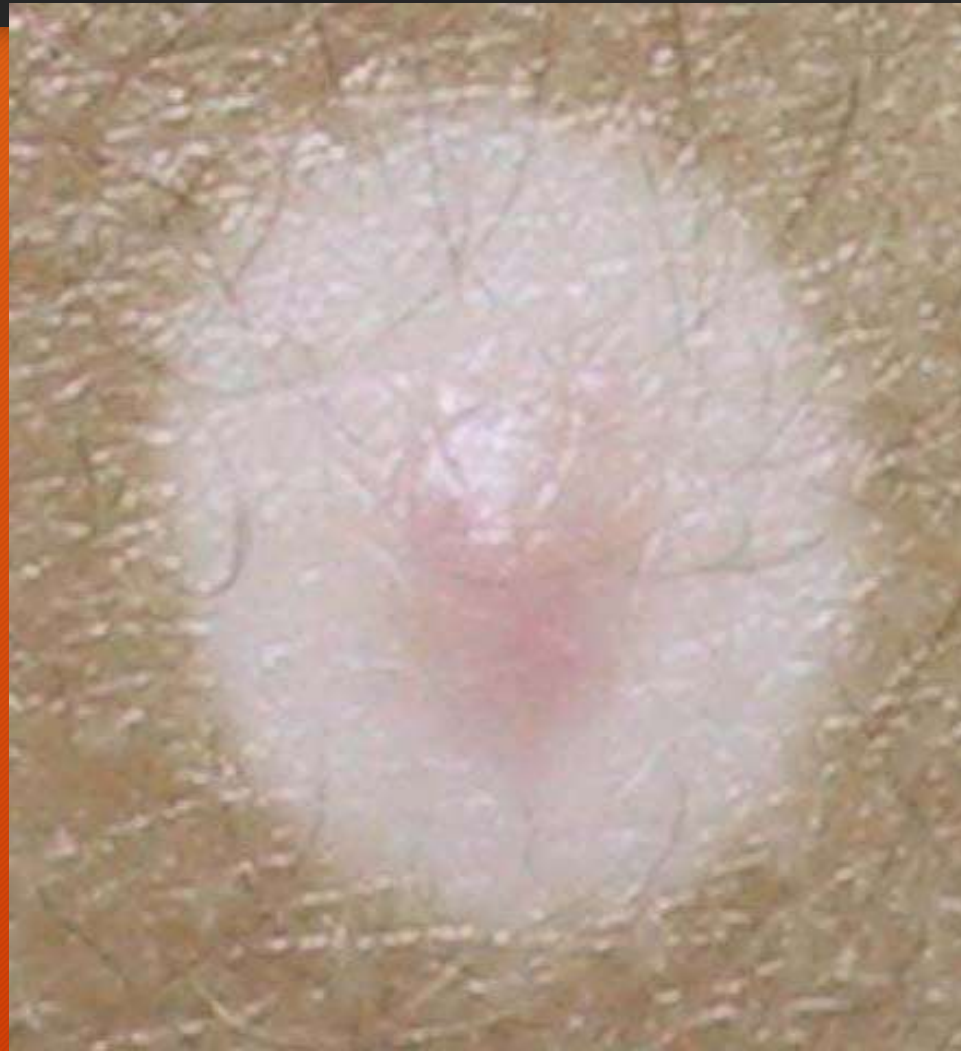# Halo Nevi

- Check central mole
- If concerning biopsy mole
- If patient is over 40, biopsy the mole
- May be seen as part of the picture of vitiligo or metastatic melanoma
- No specific treatment

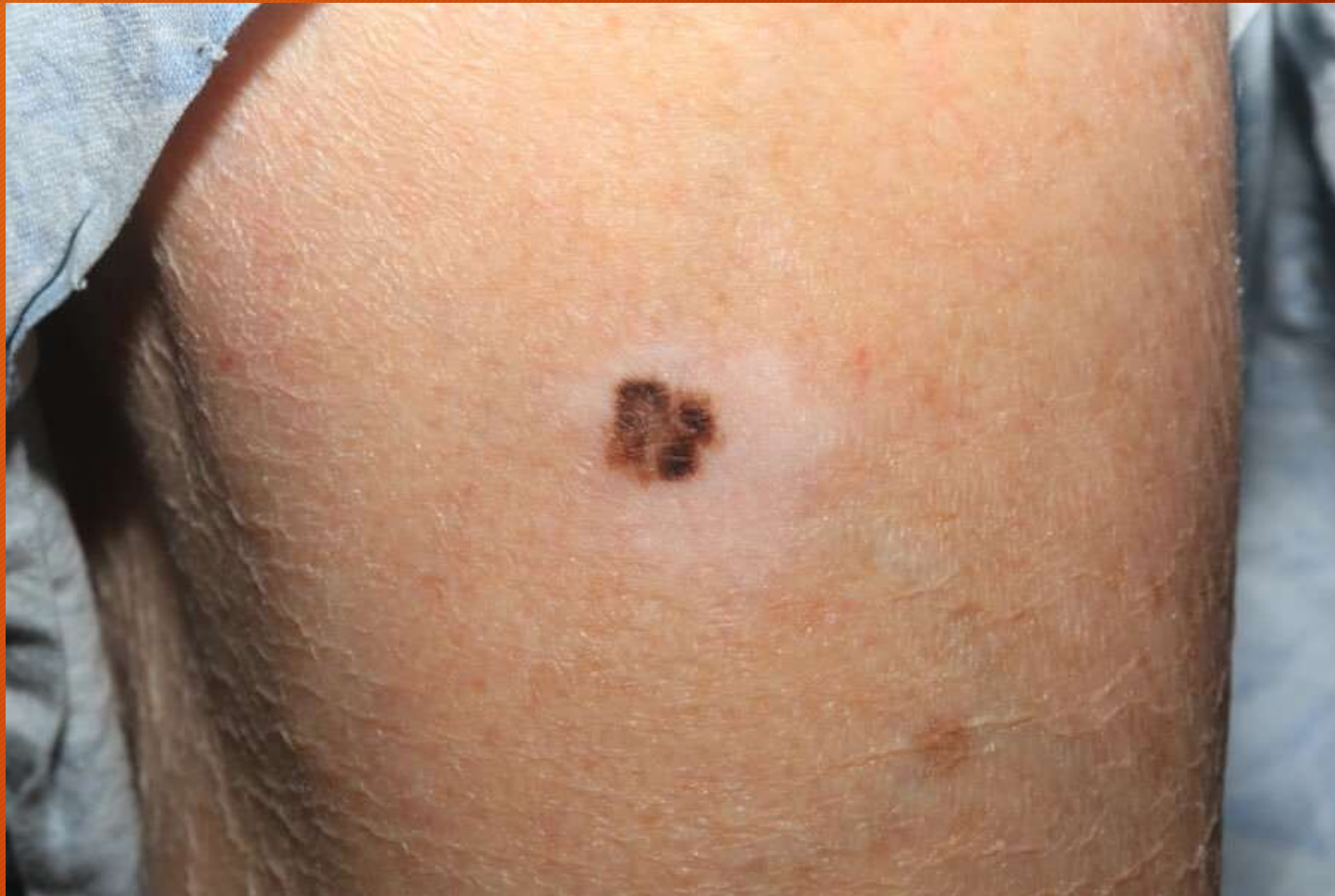# Halo Nevus



# Halo Nevus



# Halo Melanoma



# White Lesions - Summary

- More common with the increase in populations with darker skin tones
- Have a differential diagnosis
- Most conditions can be diagnosed clinically