

REVIEW ARTICLE

Edward W. Campion, M.D., *Editor*

Evaluation and Management of Lower-Extremity Ulcers

Adam J. Singer, M.D., Apostolos Tassiopoulos, M.D.,
and Robert S. Kirsner, M.D., Ph.D.

LOWER-EXTREMITY ULCERS ARE VERY COMMON, WITH AN ESTIMATED prevalence of 1 to 2% among U.S. adults,¹ and they have a major effect on public health. Lower-extremity ulcers are divided into two groups — leg ulcers and foot ulcers — because of differences in causes, pathogenesis, and treatment. Even with the best care currently available, 25 to 50% of leg ulcers and more than 30% of foot ulcers are not fully healed after 6 months of treatment. Approximately 70% of leg ulcers are caused by venous disease, and roughly 20% are caused by arterial insufficiency or mixed arteriovenous disease.^{1,2} Approximately 85% of foot ulcers are caused by peripheral neuropathy, often complicated by arterial disease.

Risk factors for venous leg ulcers include advanced age, female sex, family history of venous leg ulcer, white race, history of deep-vein thrombosis or phlebitis, previous leg injury, chronic leg edema, sedentary lifestyle, and prolonged standing. Risk factors for any arterial ulcers include diabetes mellitus, hypertension, hyperlipidemia, obesity, and smoking.³⁻⁶ Risk factors for foot ulcers include lack of sensation, limited joint mobility, anatomical abnormalities, diabetes mellitus, vascular disease, and repetitive high pressure.

The annual costs associated with venous leg ulcers and diabetic foot ulcers in the United States are approximately \$14.9 billion⁷ and \$9 billion to \$13 billion,⁸ respectively. Patients with venous leg ulcers require more medical resources than patients in a demographically matched control population.⁷ They also miss more days of work, owing to ulcer-related complications or need for follow-up, which results in costs from the loss of work that are nearly a third higher than those in a matched population. Patients with diabetic foot ulcers are often hospitalized more frequently, require more home health care, and have more emergency department visits and outpatient office visits than patients in a matched population.⁸

In this article, we describe our approach to the management of lower-extremity ulcers. Whenever possible, we have based our recommendations on findings from randomized trials. Because some recommendations are based on findings from small, observational studies or expert opinion, we recognize that there is disagreement regarding some recommended approaches; nevertheless, the approach we advise has been shown to be useful in our practices.

PATHOPHYSIOLOGICAL FEATURES OF ULCER TYPES

VENOUS ULCERS

When the valves in leg veins are damaged or the veins are dilated, retrograde blood flow results in venous hypertension. Sustained ambulatory venous pressure leads to extraction of fluid and proteins, which causes edema and extravasation of red cells that results in hemosiderin deposition and pigmentation. Mechanical disrupt-

From Departments of Emergency Medicine and Vascular Surgery, Stony Brook University, Stony Brook, NY (A.J.S., A.T.); and the Department of Dermatology and Cutaneous Surgery, University of Miami Miller School of Medicine, Miami (R.S.K.). Address reprint requests to Dr. Singer at the Department of Emergency Medicine, Stony Brook University, HSC L4-080, 8350 SUNY, Stony Brook, NY 11794-8350, or at adam.singer@stonybrook.edu.

N Engl J Med 2017;377:1559-67.

DOI: 10.1056/NEJMr1615243

Copyright © 2017 Massachusetts Medical Society.

tion of the endothelial cells and their glycocalyx coating results in margination and activation of white cells,⁹ which leads to persistent inflammation and oxidative stress, along with the expression of multiple cytokines and chemokines.¹⁰ Overexpression of matrix metalloproteinases alters collagen turnover and results in destruction of the dermal tissues and subsequent ulcer formation.¹¹ Pericapillary fibrin cuffs trap growth factors and disrupt the diffusion of oxygen, thereby contributing to local tissue hypoxia. The end result is open, draining wounds with overlying slough and surrounding induration.

ARTERIAL ULCERS

Arterial ulcers result from impaired tissue perfusion. In addition to intramural restriction of blood flow, extramural strangulation and mural thickening also contribute to reduced perfusion. Causes of reduced arterial blood flow include peripheral vascular disease due to atherosclerosis, macrovascular and microvascular disease due to diabetes mellitus, vasculitis, and microthrombi.² Reduced perfusion of the skin and soft tissues results in ischemia and subsequent necrosis, leading to leg ulceration. Recurring episodes of ischemia and reperfusion also contribute to tissue injury.¹²

DIABETIC ULCERS

Causes of diabetic foot ulcers are multifactorial and include arterial insufficiency and neuropathy, which confer a predisposition to injury and ulcer formation.¹³⁻¹⁶ The loss of protective sensation in patients with diabetes makes them vulnerable to physical trauma; therefore, patients with diabetes should receive meticulous foot care and undergo frequent inspection of their feet. Deficient sweating and altered perfusion in the foot lead to dry skin that is easily injured by minimal and repetitive trauma.¹³⁻¹⁵ Autonomic neuropathy leads to foot deformities (e.g., the Charcot foot) that result in pressure over prominent areas of the foot.¹⁶ Other abnormalities related to diabetes mellitus (such as defective white-cell function) impair wound healing and lead to the perpetuation of ulcers and secondary infection.

PRESSURE ULCERS

Pressure ulcers are caused by unrelieved pressure over bony prominences such as the heel and usually develop in nonambulatory patients. Prolonged

compression of the tissues, along with friction and shear, results in local tissue ischemia and necrosis, which lead to ulcer formation.¹⁷

DIAGNOSIS

IDENTIFYING ULCER TYPE

Most ulcer types can be identified on the basis of their appearance and location (Fig. 1). History taking should focus on coexisting medical conditions, such as diabetes mellitus, peripheral arterial disease, and deep-vein thrombosis, that may point to the underlying cause of the ulcer. In addition to an examination of the wound and surrounding skin, physical examination should include a neurovascular evaluation aimed at identifying neuropathy and arterial insufficiency.

Venous Ulcers

Venous leg ulcers typically occur over the medial aspect of the lower leg between the lower calf and the medial malleolus and are associated with edema, pigment deposition (combined hemosiderin and melanin), venous dermatitis, atrophie blanche (porcelain white scars, telangiectasia, and dyspigmentation), and lipodermatosclerosis. Patients often report aching or burning pain (or both) and swelling in the leg that progress during the day and lessen with leg elevation. A patient's history may also include deep-vein thrombosis, trauma, or surgery in the affected leg. Venous leg ulcers are shallow and irregularly shaped and contain granulation tissue or yellow fibrin (Fig. 1). Venous reflux can be diagnosed by means of duplex ultrasonography of the lower leg.

Arterial Ulcers

Arterial ulcers are more common among smokers and among patients with diabetes mellitus, those with hyperlipidemia, and those with hypertension. Patients may have a history of intermittent claudication or pain while at rest that worsens when the leg is elevated and lessens when the leg is in a dependent position. Arterial ulcers may involve the distal foot at areas of trauma (e.g., toes and heels) and the anterior aspect of the leg where arterial redundancy is lacking. The ulcers are often dry and appear "punched out," with well-demarcated edges and a pale, non-granulating necrotic base (Fig. 1). Arterial ulcers may also be very deep. Findings of abnormal pedal pulses, coolness in only one leg or foot, a



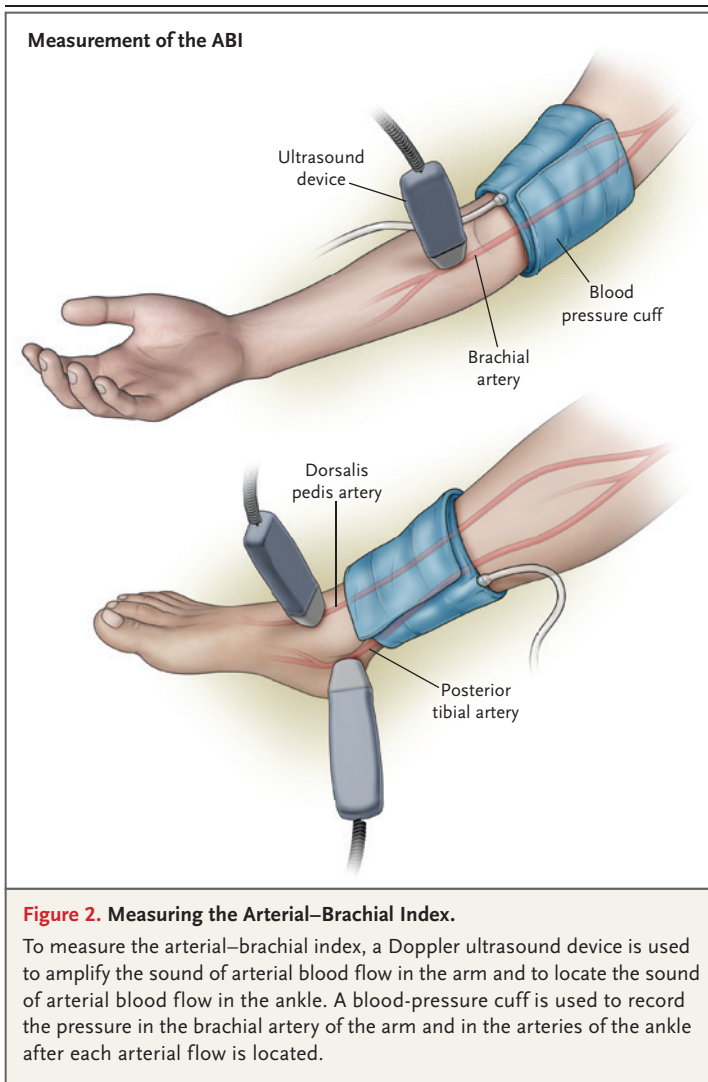
| Feature | Ulcer Type | | | |
|--------------------------|---|---|---|---|
| | Venous | Arterial | Neuropathic Diabetic | Pressure |
| Underlying condition | Varicose veins, previous deep-vein thrombosis, obesity, pregnancy, recurrent phlebitis | Diabetes, hypertension, smoking, previous vascular disease | Diabetes, trauma, prolonged pressure | Limited mobility |
| Ulcer location | Area between the lower calf and the medial malleolus | Pressure points, toes and feet, lateral malleolus and tibial areas | Plantar aspect of foot, tip of the toe, lateral to fifth metatarsal | Bony prominences, heel |
| Ulcer characteristic | Shallow and flat margins, moderate-to-heavy exudate, slough at base with granulation tissue | Punched out and deep, irregular shape, unhealthy wound bed, presence of necrotic tissue, minimal exudate unless infected | Deep, surrounded by callus, insensate | Deep, often macerated |
| |  |  |  |  |
| Condition of leg or foot | Hemosiderin staining, thickening and fibrosis, eczematous and itchy skin, limb edema, normal capillary refill | Thin shiny skin, reduced hair growth, cool skin, pallor on leg elevation, absent or weak pulses, delayed capillary refill, gangrene | Dry, cracked, insensate, calluses | Atrophic skin, loss of muscle mass |
| Treatment | Compression therapy, leg elevation, surgical management | Revascularization, anti-platelet medications, management of risk factors | Off-loading of pressure, topical growth factors | Off-loading of pressure; reduction of excessive moisture, shear, and friction; adequate nutrition |

Figure 1. Venous, Arterial, Neuropathic Diabetic, and Pressure Ulcers.

prolonged venous filling time, and a femoral bruit facilitate the diagnosis of peripheral arterial disease.¹⁸ Findings of delayed capillary refill and discoloration, skin atrophy, and lack of hair on the foot are probably not helpful in establishing a diagnosis. An ischemic foot sometimes appears pink and is relatively warm because of arteriovenous shunting. Leg elevation may worsen pain, because it results in drainage of blood, and the foot becomes pale (elevation pallor).

Delayed return of red color or prolonged venous filling when the leg is in a dependent position may also be signs of decreased perfusion.

In addition to palpation of arterial pulses in the leg and foot, a simple method for identifying decreased lower-extremity perfusion is measurement of the ankle-brachial index (ABI). The measurements are performed with a standard blood-pressure cuff and a Doppler ultrasound device (Fig. 2). An ABI lower than 0.9 indicates arterial



insufficiency and should lead to further investigation by a vascular surgeon.¹⁹ Lower ABIs are associated with more severe vascular disease, and ABIs lower than 0.5 are often seen in patients who have ulcers that developed as a result of arterial insufficiency. Falsely normal or even elevated ABIs may be seen in patients with non-compressible vessels, in patients with diabetes that is caused by glycation of blood vessels, and in elderly patients with vessel calcification. Computed tomographic angiography and magnetic resonance angiography may be used if the diagnosis is unclear. Transcutaneous oxygen tension (oxygen level of the tissue below the skin), when it can be measured, is a good indicator of critical limb ischemia. A recent meta-analysis showed that a transcutaneous oxygen tension of 20 mm Hg

was a valid cutoff value for predicting the need for limb amputation and that a transcutaneous oxygen tension of 30 mm Hg was an appropriate value for predicting wound healing after limb amputation.²⁰

Neuropathic Diabetic Ulcers

Neuropathy usually occurs in patients with diabetes mellitus and is an important risk factor for foot ulceration. A simple blood-sugar (or glycated hemoglobin) measurement should be obtained to assess for hyperglycemia, and a sensory examination of the legs and feet should be performed to assess for neuropathy. Neuropathic ulcers are usually located at sites of trauma (often repetitive) or at sites of prolonged pressure such as the tip of the toe (e.g., because of hammer toe), the medial side of the first metatarsal phalangeal joint, or the plantar surface of the feet (Fig. 1). A simple assessment that uses a 10-g filament has been validated as a measure of the foot's ability to detect sensation, regardless of whether it is performed along with an assessment of the foot's ability to sense vibration from a standard tuning fork.²¹ Testing for neuropathy should not be performed over areas of callus.²²

Pressure Ulcers

Pressure ulcers occur because of the inability to sense (e.g., neuropathy) or relieve (e.g., debilitation) prolonged pressure over the skin, typically on the heel of the foot. Skin atrophy and loss of muscle mass, common conditions in debilitated patients, further contribute to the susceptibility to pressure-ulcer formation.

IDENTIFYING INFECTION

Although recognition of infection in lower-extremity ulcers may be difficult, it is essential. Of all lower-extremity ulcers, diabetic foot ulcers are the most prone to infection, with more than half involving clinical infection at the time of a patient's presentation to a health care practitioner.²³ Early identification of infection in diabetic foot ulcers is critical, because one in five patients with an infected foot will eventually undergo amputation.²⁴ Diagnosis of infection is made clinically and should not be based on findings from wound-surface swabs. Microbiologic findings support and direct antibiotic therapy. Signs and symptoms of localized infection include local warmth, erythema, tenderness or pain, swelling,

and purulent discharge. Systemic infection and subsequent host response is suggested by the presence of fever, chills, leukocytosis, and expanding erythema and lymphangitis. Deep swabbing of the wound, aspiration of purulent discharge, and tissue biopsies can help identify a causative agent and may assist in identifying the appropriate antibiotic therapy, if initial antibiotic therapy is unsuccessful. Most acute infections that have not been treated with antibiotics are caused by gram-positive organisms such as staphylococci.²⁵ Chronic infections, especially after administration of antibiotics, are generally polymicrobial, with gram-positive, gram-negative, and anaerobic bacteria.²⁶ Severe necrotizing infections are characterized by the presence of crepitus, bullae, and extensive necrosis and warrant urgent consultation with a vascular surgeon. Underlying osteomyelitis is not uncommon in diabetic foot ulcers and should be suspected in the case of deep, chronic ulcers over bones. A sterile blunt metal probe can be inserted into the depth of the wound. In hospitalized patients, osteomyelitis can be diagnosed with greatest predictive value by identification of bone at the depth of the ulcer (hard gritty feel).²⁷ Although the criterion standard for diagnosing osteomyelitis is a bone biopsy, infections can be confirmed by noninvasive methods such as plain radiography or magnetic resonance imaging, which is more sensitive than plain radiography.²⁸

TREATMENT

GENERAL PRINCIPLES

There are a number of guidelines for the management of lower-extremity ulcers.²⁸⁻³⁴ General principles of management include wound débridement, infection control, application of dressings, off-loading of localized pressure, and treatment of underlying conditions such as diabetes mellitus and peripheral arterial disease. Lifestyle changes (e.g., smoking cessation and dietary modifications) should also be made to help manage underlying diseases.

Wound Débridement

Débridement, which involves removal of devitalized tissue, reduces bacterial burden.³⁵⁻³⁷ Careful, sharp surgical débridement (with the use of a scalpel, sharp scissors, or both) down to viable bleeding tissue, with removal of senescent fibro-

blasts in the wound bed and phenotypically and genotypically abnormal keratinocytes at the edge of the wound, is the most rapid method. Autolytic dressings (such as alginates, hydrocolloids, and hydrogels) and enzymatic agents (such as collagenase) may also be considered³⁸; although these options are slower than surgical débridement, they are less painful and traumatic.

Infection Control

A systematic review of 45 randomized, controlled trials involving a total of 4486 patients showed no evidence that supported the routine use of prophylactic systemic antibiotics for lower-extremity ulcers.³⁹ Although the review showed evidence that supported the topical use of cadexomer iodine, no evidence supported the prolonged or routine use of silver-based or honey-based products in noninfected wounds.³⁹ In our practices, topical cadexomer is used for contaminated ulcers that have no clear-cut evidence of infection and as an adjunct to systemic antibiotics in infected ulcers.

If infection is suspected because of the presence of malodorous purulent discharge or because healing does not progress after routine débridement, infection can be confirmed with tissue biopsies (if available) or validated quantitative wound swabs (these are not required in the case of obvious infection).^{30,34} For ulcers that have a high bacterial burden ($>10^6$ colony-forming units per gram of tissue or any level of beta-hemolytic streptococci) after adequate débridement, topical or systemic antibiotic therapy targeting gram-positive bacteria should be started, such as dicloxacillin, cephalexin, or clindamycin. In our practices, topical antibiotics are used first, unless there is evidence of obvious infection. Because of the multiple bacterial causes in patients with diabetes, wide-spectrum systemic antibiotics that cover gram-positive and gram-negative bacteria as well as anaerobes should be used in these patients. Potential agents include a combination of a penicillin and a beta-lactamase inhibitor or a fluoroquinolone or linezolid alone.

Patients with spreading erythema from cellulitis or clinically significant evidence of systemic infection (e.g., fever, chills, or lymphangitis), patients with clinically significant coexisting medical or immunocompromising conditions (e.g., uncontrolled diabetes mellitus or use of systemic glucocorticoids), and patients with local infection that is worsening or not responding to

oral antibiotic agents should generally receive intravenous antibiotics. Consultation with an infectious disease specialist should be considered for refractory or complex infections.

Wound Dressings

Wound dressings that promote an appropriate level of moisture (while limiting maceration) and protect the ulcer from further injury and shear stress should be used. A large number of wound dressings are available, including hydrocolloids, alginates, and foams. Many advanced dressings may be left in place for up to a week unless they are malodorous or saturated with exudate. The decision of which dressing to use should be based on the preferences of the patient and practitioner. In general, dry wounds should be treated with moisture-promoting dressings, whereas exudative wounds should be managed with absorptive dressings. Dressings are also available in combination with antiseptic agents (e.g., nanoparticles of silver); these may be helpful in the short term to reduce the concentration of bacteria when infection is present, but they are not recommended for long-term use. Foam dressings, despite their frequent use, are no more effective than other standard dressings.⁴⁰

Pressure Relief

Avoiding or minimizing pressure over bony prominences plays a vital role in the prevention and management of pressure ulcers.³³ Proactive assessment of the risk of pressure ulcers (e.g., the Braden scale) should be performed in all hospitalized patients.⁴¹ Frequent repositioning of patients and the use of pressure-reducing surfaces (e.g., an alternating pressure mattress) and orthotics that relieve pressure from the ulcer and minimize shear stress are recommended.⁴²⁻⁴⁴

SPECIFIC THERAPIES BASED ON THE TYPE OF ULCER

Venous Ulcers

Compression therapy is strongly recommended for venous leg ulcers.³⁰ The compression dressing is applied from the toes to the knees and should include the heel. Graded pressure is applied, with more pressure applied distally. Each successive wrap should overlap the previous one by 50%. Several large clinical trials and systematic reviews have concluded that compression therapy, as compared with no compression, promotes the healing of venous leg ulcers and re-

duces the risk of recurrence and is similar to surgical intervention.^{45,46} Multicomponent systems that contain an elastic bandage appear to be more effective than those that have only inelastic components. The recommended compression pressures for the treatment of venous leg ulcers with varicose veins, the postthrombotic syndrome, or lymphedema are between 30 and 40 mm Hg.⁴⁶

In our practices, we modify compression therapy in patients with mild-to-moderate arterial disease (e.g., an ABI between 0.5 and 0.8) by using inelastic wraps or by reducing the number of layers of compression, and we follow the patients weekly to ensure that arterial flow is adequate. In severe cases (ABI <0.5), compression should not be used because it may further reduce arterial flow. Venous ablation appears to reduce the incidence of recurrence and may facilitate the healing of venous leg ulcers, although evidence for this from well-performed studies is still lacking. A meta-analysis of studies that included patients with venous leg ulcers indicated that 45% of all ulcers are due to superficial vein reflux only, and 88% of patients with venous leg ulcers have reflux in the superficial system.⁴⁷ Superficial vein reflux can be treated with outpatient procedures such as sclerotherapy or venous ablation with the use of laser or radiofrequency.⁴⁸

Because inflammation is thought to play a role in the pathogenesis of venous leg ulcers, two small randomized, controlled trials evaluated the efficacy of adding aspirin, administered orally at a dose of 300 mg per day, to compression therapy; the results suggested a benefit.⁴⁹ However, the small sample size and issues related to study quality (short follow-up and poor description of placebo) limit the ability to draw conclusions regarding the benefits and harms of regular use of aspirin for venous leg ulcers. In our practices, aspirin is used in patients with venous leg ulcers when not contraindicated.

Despite a lack of data from randomized, controlled trials, autologous split-thickness skin grafting is often used for débrided, noninfected, chronic lower-extremity ulcers that fail to heal, especially venous leg ulcers, with a success rate of up to 90% at 5 years.⁵⁰ Because surgery (e.g., high ligation and vein stripping) has been shown to reduce the incidence of recurrence of venous leg ulcers,⁵¹ patients with chronic lower-extremity ulcers that have not healed despite débridement should be considered for referral to a vascular

surgeon for consideration of venous intervention. Endovenous intervention with compression may be considered for venous leg ulcers that are caused by small varicose veins other than those of the saphenous type.⁵²

Arterial Ulcers

The most effective method to accelerate healing of arterial ulcers is to restore local blood flow by revascularization.³¹ A systematic review of the effectiveness of revascularization of the ulcerated foot by endovascular therapies or by surgical bypass techniques in patients with diabetes mellitus and peripheral arterial disease concluded that there were insufficient data to recommend one method of revascularization over another.⁵³ The decision of whether to perform an endovascular procedure or open bypass surgery should be based on the characteristics and preferences of the patient, as well as on the experience and preferences of the surgeon.

Neuropathic Diabetic and Pressure Ulcers

Careful inspection of the patient's footwear may help identify improper fit, wear and tear, or the presence of foreign bodies that contribute to ulcer formation. Off-loading of pressure in neuropathic ulcers is essential. Off-loading may be achieved with the use of total-contact casts (i.e., nonremovable casts), removable boots, instant total-contact casts (i.e., removable walking casts that are made nonremovable by the addition of plaster), fiberglass boots, and wheelchairs — and to a lesser extent with healing sandals, crutches, and walkers.^{22,54} In two meta-analyses, nonremovable methods (total-contact casts or instant total-contact casts) were more effective at healing plantar ulcers than removable methods (relative rate of healing, 1.43⁵⁵ and 1.17⁵⁶). Specialized pressure-measurement systems that measure off-loading while the patient is walking barefoot or wearing a shoe may help tailor therapy.⁵⁷ Patients should also be referred to a foot and ankle specialist to consider correction of any bone abnormalities. However, many surgical off-loading procedures are more effective in preventing ulcer recurrence than in treating active ulcers.⁵⁸

ADVANCED THERAPIES

If a wound does not respond to standard care (with response typically defined as a reduction in wound size of 30% for venous leg ulcers and

50% for diabetic foot ulcers within 4 weeks after the initiation of treatment), advanced care and referral to a wound specialist are indicated. For venous leg ulcers, adjunctive treatments that are considered to speed healing include oral medications such as pentoxifylline,⁵⁹ aspirin,⁴⁹ simvastatin,⁶⁰ and sulodexide,⁶¹ as well as cell-based and tissue-based products such as bilayered living skin construct,⁶² porcine small-intestine submucosa,⁶³ a synthetic matrix made of poly-N-acetyl glucosamine,⁶⁴ or granulocyte-macrophage colony-stimulating factor.⁶⁵ Adjunctive therapies that may be considered for diabetic foot ulcers include platelet-derived growth factor,⁶⁶ platelet-rich plasma,⁶⁷ placental membranes,⁶⁸ human amniotic membrane,⁶⁹ bilayered skin equivalent,⁷⁰ dermal skin substitutes,^{71,72} negative-pressure wound therapy,⁷³ and hyperbaric oxygen therapy.⁷⁴ Other therapies that have shown promise include ultrasound therapy,⁷⁵ electrical stimulation,⁷⁶ extracorporeal shock-wave therapy,⁷⁷ and spinal cord stimulation.⁷⁸ Further details of advanced therapies for lower-extremity ulcers are provided in Table S1 in the Supplementary Appendix, available with the full text of this article at NEJM.org.

PATIENT DISPOSITION

Patients with any limb-threatening or life-threatening conditions should be admitted to the hospital, and a vascular surgeon or wound specialist should be consulted immediately. Patients with systemic infection and patients with expanding local infection that does not respond to oral antibiotics should be admitted to the hospital to receive intravenous antibiotics. Patients who cannot care for themselves or their wounds may require home health care or admission to a skilled nursing facility or hospital. All other patients may be treated with a wound dressing and off-loading of pressure (when indicated) and referred to their primary care physician or wound specialist. Referral to an orthotist for prosthetic footwear evaluation as a preventive measure should also be considered. Finally, given the burden of lower-extremity ulcers, health care practitioners should focus not only on early intervention but also on prevention in patients at risk for lower-extremity ulcers.

No potential conflict of interest relevant to this article was reported.

Disclosure forms provided by the authors are available with the full text of this article at NEJM.org.

REFERENCES

1. Alavi A, Sibbald RG, Phillips TJ, et al. What's new: management of venous leg ulcers: approach to venous leg ulcers. *J Am Acad Dermatol* 2016;74:627-40.
2. Agale SV. Chronic leg ulcers: epidemiology, aetiopathogenesis, and management. *Ulcers 2013* (<https://www.hindawi.com/journals/ulcers/2013/413604/>).
3. Margolis DJ, Bilker W, Santanna J, Baumgarten M. Venous leg ulcer: incidence and prevalence in the elderly. *J Am Acad Dermatol* 2002;46:381-6.
4. Carpentier PH, Maricq HR, Biro C, Ponçot-Makinen CO, Franco A. Prevalence, risk factors, and clinical patterns of chronic venous disorders of lower limbs: a population-based study in France. *J Vasc Surg* 2004;40:650-9.
5. Beebe-Dimmer JL, Pfeifer JR, Engle JS, Schottenfeld D. The epidemiology of chronic venous insufficiency and varicose veins. *Ann Epidemiol* 2005;15:175-84.
6. Mekkes JR, Loots MA, Van Der Wal AC, Bos JD. Causes, investigation and treatment of leg ulceration. *Br J Dermatol* 2003;148:388-401.
7. Rice JB, Desai U, Cummings AK, Birnbaum HG, Skornicki M, Parsons N. Burden of venous leg ulcers in the United States. *J Med Econ* 2014;17:347-56.
8. Rice JB, Desai U, Cummings AKG, Birnbaum HG, Skornicki M, Parsons NB. Burden of diabetic foot ulcers for Medicare and private insurers. *Diabetes Care* 2014;37:651-8.
9. Raffetto JD. Pathophysiology of wound healing and alterations in venous leg ulcers — review. *Phlebology* 2016;31:Suppl:56-62.
10. Gohel MS, Windhaber RA, Tarlton JF, Whyman MR, Poskitt KR. The relationship between cytokine concentrations and wound healing in chronic venous ulceration. *J Vasc Surg* 2008;48:1272-7.
11. Mannello F, Raffetto JD. Matrix metalloproteinase activity and glycosaminoglycans in chronic venous disease: the linkage among cell biology, pathology and translational research. *Am J Transl Res* 2011;3:149-58.
12. Zhao R, Liang H, Clarke E, Jackson C, Xue M. Inflammation in chronic wounds. *Int J Mol Sci* 2016;17:E2085.
13. Lepäntalo M, Apelqvist J, Setacci C, et al. Chapter V: diabetic foot. *Eur J Vasc Endovasc Surg* 2011;42:Suppl 2:S60-S74.
14. Clayton W, Elasy TA. A review of the pathophysiology, classification, and treatment of foot ulcers in diabetic patients. *Clin Diabetes* 2009;27:52-8.
15. Schaper NC, Huijberts M, Pickwell K. Neurovascular control and neurogenic inflammation in diabetes. *Diabetes Metab Res Rev* 2008;24:Suppl 1:S40-S44.
16. Alavi A, Sibbald RG, Mayer D, et al. Diabetic foot ulcers: Part I. Pathophysiology and prevention. *J Am Acad Dermatol* 2014;70(1):1.e18-18.
17. Thomas DR. Does pressure cause pressure ulcers? An inquiry into the etiology of pressure ulcers. *J Am Med Dir Assoc* 2010;11:397-405.
18. McGee SR, Boyko EJ. Physical examination and chronic lower-extremity ischemia: a critical review. *Arch Intern Med* 1998;158:1357-64.
19. Khan TH, Farooqui FA, Niazi K. Critical review of the ankle brachial index. *Curr Cardiol Rev* 2008;4:101-6.
20. Nishio H, Minakata K, Kawaguchi A, et al. Transcutaneous oxygen pressure as a surrogate index of lower limb amputation. *Int Angiol* 2016;35:565-72.
21. Perkins BA, Olaleye D, Zinman B, Brill V. Simple screening tests for peripheral neuropathy in the diabetes clinic. *Diabetes Care* 2001;24:250-6.
22. Best practice guidelines: wound management in diabetic foot ulcers. London: Wounds International, 2013 (<http://www.woundsinternational.com/best-practices/view/best-practice-guidelines-wound-management-in-diabetic-foot-ulcers>).
23. Lavery LA, Armstrong DG, Wunderlich RP, Mohler MJ, Wendel CS, Lipsky BA. Risk factors for foot infections in individuals with diabetes. *Diabetes Care* 2006;29:1288-93.
24. Wu SC, Driver VR, Wrobel JS, Armstrong DG. Foot ulcers in the diabetic patient, prevention and treatment. *Vasc Health Risk Manag* 2007;3:65-76.
25. Noor S, Zubair M, Ahmad J. Diabetic foot ulcer — a review on pathophysiology, classification and microbial etiology. *Diabetes Metab Syndr* 2015;9:192-9.
26. Howell-Jones RS, Wilson MJ, Hill KE, Howard AJ, Price PE, Thomas DW. A review of the microbiology, antibiotic usage and resistance in chronic skin wounds. *J Antimicrob Chemother* 2005;55:143-9.
27. Morales Lozano R, González Fernández ML, Martínez Hernández D, Benítez Montesinos JV, Guisado Jiménez S, González Jurado MA. Validating the probe-to-bone test and other tests for diagnosing chronic osteomyelitis in the diabetic foot. *Diabetes Care* 2010;33:2140-5.
28. Lipsky BA, Berendt AR, Cornia PB, et al. 2012 Infectious Diseases Society of America clinical practice guideline for the diagnosis and treatment of diabetic foot infections. *Clin Infect Dis* 2012;54(12):e132-73.
29. Kirsner RS. The Wound Healing Society chronic wound ulcer healing guidelines update of the 2006 guidelines — blending old with new. *Wound Repair Regen* 2016;24:110-1.
30. Marston W, Tang J, Kirsner RS, Ennis W. Wound Healing Society 2015 update on guidelines for venous ulcers. *Wound Repair Regen* 2016;24:136-44.
31. Federman DG, Ladijnski B, Dardik A, et al. Wound Healing Society 2014 update on guidelines for arterial ulcers. *Wound Repair Regen* 2016;24:127-35.
32. Lavery LA, Davis KE, Berriman SJ, et al. WHS guidelines update: diabetic foot ulcer treatment guidelines. *Wound Repair Regen* 2016;24:112-26.
33. Gould L, Stuntz M, Giovannelli M, et al. Wound Healing Society 2015 update on guidelines for pressure ulcers. *Wound Repair Regen* 2016;24:145-62.
34. Alavi A, Sibbald RG, Phillips TJ, et al. What's new: management of leg ulcers. *J Am Acad Dermatol* 2016;74:643-64.
35. Cardinal M, Eisenbud DE, Armstrong DG, et al. Serial surgical debridement: a retrospective study on clinical outcomes in chronic lower extremity wounds. *Wound Repair Regen* 2009;17:306-11.
36. Williams D, Enoch S, Miller D, Harris K, Price P, Harding KG. Effect of sharp debridement using curette on recalcitrant nonhealing venous leg ulcers: a concurrently controlled, prospective cohort study. *Wound Repair Regen* 2005;13:131-7.
37. Gethin G, Cowman S, Kolbach DN. Debridement for venous leg ulcers. *Cochrane Database Syst Rev* 2015;9:CD008599.
38. König M, Vanscheidt W, Augustin M, Kapp H. Enzymatic versus autolytic debridement of chronic leg ulcers: a prospective randomised trial. *J Wound Care* 2005;14:320-3.
39. O'Meara S, Al-Kurdi D, Ologun Y, Ovington LG, Martyn-St James M, Richardson R. Antibiotics and antiseptics for venous leg ulcers. *Cochrane Database Syst Rev* 2014;1:CD003557.
40. O'Meara S, Martyn-St James M. Foam dressings for venous leg ulcers. *Cochrane Database Syst Rev* 2013;5:CD009907.
41. Comfort EH. Reducing pressure ulcer incidence through Braden Scale risk assessment and support surface use. *Adv Skin Wound Care* 2008;21:330-4.
42. Norton L, Coulters P, Sibbald RG. Beds: practical pressure management for surfaces/mattresses. *Adv Skin Wound Care* 2011;24:324-32.
43. Sprigle S, Sonenblum S. Assessing evidence supporting redistribution of pressure for pressure ulcer prevention: a review. *J Rehabil Res Dev* 2011;48:203-13.
44. Bus SA. The role of pressure offloading on diabetic foot ulcer healing and prevention of recurrence. *Plast Reconstr Surg* 2016;138:Suppl:179S-187S.
45. Gohel MS, Barwell JR, Taylor M, et al. Long term results of compression therapy alone versus compression plus surgery in chronic venous ulceration (ESCHAR): randomised controlled trial. *BMJ* 2007;335:83.
46. O'Meara S, Cullum N, Nelson EA, Dumville JC. Compression for venous leg ulcers. *Cochrane Database Syst Rev* 2012;11:CD000265.
47. Tassiopoulos AK, Golts E, Oh DS, Labropoulos N. Current concepts in chronic venous ulceration. *Eur J Vasc Endovasc Surg* 2000;20:227-32.
48. Kuyumcu G, Salazar GM, Prabhakar

- AM, Ganguli S. Minimally invasive treatments for perforator vein insufficiency. *Cardiovasc Diagn Ther* 2016;6:593-8.
49. de Oliveira Carvalho PE, Magolbo NG, De Aquino RF, Weller CD. Oral aspirin for treating venous leg ulcers. *Cochrane Database Syst Rev* 2016;2:CD009432.
50. Serra R, Rizzuto A, Rossi A, et al. Skin grafting for the treatment of chronic leg ulcers — a systematic review in evidence-based medicine. *Int Wound J* 2017;14:149-57.
51. Howard DP, Howard A, Kothari A, Wales L, Guest M, Davies AH. The role of superficial venous surgery in the management of venous ulcers: a systematic review. *Eur J Vasc Endovasc Surg* 2008;36:458-65.
52. Tisi PV, Beverley C, Rees A. Injection sclerotherapy for varicose veins. *Cochrane Database Syst Rev* 2006;4:CD001732.
53. Hinchliffe RJ, Brownrigg JRA, Andros G, et al. Effectiveness of revascularization of the ulcerated foot in patients with diabetes and peripheral artery disease: a systematic review. *Diabetes Metab Res Rev* 2016;32:Suppl 1:136-44.
54. Van Netten JJ, Price PE, Lavery LA, et al. Prevention of foot ulcers in the at-risk patient with diabetes: a systematic review. *Diabetes Metab Res Rev* 2016;32:Suppl 1:84-98.
55. Morona JK, Buckley ES, Jones S, Reddin EA, Merlin TL. Comparison of the clinical effectiveness of different off-loading devices for the treatment of neuropathic foot ulcers in patients with diabetes: a systematic review and meta-analysis. *Diabetes Metab Res Rev* 2013;29:183-93.
56. Lewis J, Lipp A. Pressure-relieving interventions for treating diabetic foot ulcers. *Cochrane Database Syst Rev* 2013;1:CD002302.
57. Bus SA, Haspels R, Busch-Westbroek TE. Evaluation and optimization of therapeutic footwear for neuropathic diabetic foot patients using in-shoe plantar pressure analysis. *Diabetes Care* 2011;34:1595-600.
58. Bus SA, van Deursen RW, Armstrong DG, Lewis JE, Caravaggi CF, Cavanagh PR. Footwear and offloading interventions to prevent and heal foot ulcers and reduce plantar pressure in patients with diabetes: a systematic review. *Diabetes Metab Res Rev* 2016;32:Suppl 1:99-118.
59. Jull AB, Arroll B, Parag V, Waters J. Pentoxifylline for treating venous leg ulcers. *Cochrane Database Syst Rev* 2012;12:CD001733.
60. Evangelista MT, Casintahan ME, Villafuerte LL. Simvastatin as a novel therapeutic agent for venous ulcers: a randomized, double-blind, placebo-controlled trial. *Br J Dermatol* 2014;170:1151-7.
61. Wu B, Lu J, Yang M, Xu T. Sulodexide for treating venous leg ulcers. *Cochrane Database Syst Rev* 2016;6:CD010694.
62. Brem H, Balledux J, Sukkariet T, Carson P, Falanga V. Healing of venous ulcers of long duration with a bilayered living skin substitute: results from a general surgery and dermatology department. *Dermatol Surg* 2001;27:915-9.
63. Mostow EN, Haraway GD, Dalsing M, Hodde JP, King D, OASIS Venous Ulcer Study Group. Effectiveness of an extracellular matrix graft (OASIS Wound Matrix) in the treatment of chronic leg ulcers: a randomized clinical trial. *J Vasc Surg* 2005;41:837-43.
64. Kelechi TJ, Mueller M, Hankin CS, Bronstone A, Samies J, Bonham PA. A randomized, investigator-blinded, controlled pilot study to evaluate the safety and efficacy of a poly-N-acetyl glucosamine-derived membrane material in patients with venous leg ulcers. *J Am Acad Dermatol* 2012;66(6):e209-e215.
65. Da Costa RM, Ribeiro Jesus FM, Aniceto C, Mendes M. Randomized, double-blind, placebo-controlled, dose-ranging study of granulocyte-macrophage colony stimulating factor in patients with chronic venous leg ulcers. *Wound Repair Regen* 1999;7:17-25.
66. Sibbald RG, Torrance G, Hux M, Attard C, Milkovich N. Cost-effectiveness of becaplermin for nonhealing neuropathic diabetic foot ulcers. *Ostomy Wound Manage* 2003;49:76-84.
67. Driver VR, Hanft J, Fylling CP, Beriou JM, Autologel Diabetic Foot Ulcer Study Group. A prospective, randomized, controlled trial of autologous platelet-rich plasma gel for the treatment of diabetic foot ulcers. *Ostomy Wound Manage* 2006;52:68-70, 72, 74.
68. Lavery LA, Fulmer J, Shebetka KA, et al. The efficacy and safety of Grafix for the treatment of chronic diabetic foot ulcers: results of a multi-centre, controlled, randomised, blinded, clinical trial. *Int Wound J* 2014;11:554-60.
69. Zelen CM, Gould L, Serena TE, Carter MJ, Keller J, Li WW. A prospective, randomised, controlled, multi-centre comparative effectiveness study of healing using dehydrated human amnion/chorion membrane allograft, bioengineered skin substitute or standard of care for treatment of chronic lower extremity diabetic ulcers. *Int Wound J* 2015;12:724-32.
70. Edmonds M, European and Australian Apligraf Diabetic Foot Ulcer Study Group. Apligraf in the treatment of neuropathic diabetic foot ulcers. *Int J Low Extrem Wounds* 2009;8:11-8.
71. Marston WA, Hanft J, Norwood P, Polak R. The efficacy and safety of Derma-graft in improving the healing of chronic diabetic foot ulcers: results of a prospective randomized trial. *Diabetes Care* 2003;26:1701-5.
72. Driver VR, Lavery LA, Reyzelman AM, et al. A clinical trial of Integra Template for diabetic foot ulcer treatment. *Wound Repair Regen* 2015;23:891-900.
73. Blume PA, Walters J, Payne W, Ayala J, Lantis J. Comparison of negative pressure wound therapy using vacuum-assisted closure with advanced moist wound therapy in the treatment of diabetic foot ulcers: a multicenter randomized controlled trial. *Diabetes Care* 2008;31:631-36.
74. Löndahl M, Katzman P, Hammarlund C, Nilsson A, Landin-Olsson M. Relationship between ulcer healing after hyperbaric oxygen therapy and transcutaneous oximetry, toe blood pressure and ankle-brachial index in patients with diabetes and chronic foot ulcers. *Diabetologia* 2011;54:65-8.
75. Kavros SJ, Miller JL, Hanna SW. Treatment of ischemic wounds with noncontact, low-frequency ultrasound: the Mayo clinic experience, 2004-2006. *Adv Skin Wound Care* 2007;20:221-6.
76. Petrofsky JS, Lawson D, Berk L, Suh H. Enhanced healing of diabetic foot ulcers using local heat and electrical stimulation for 30 min three times per week. *J Diabetes* 2010;2:41-6.
77. Omar MT, Alghadir A, Al-Wahhabi KK, Al-Askar AB. Efficacy of shock wave therapy on chronic diabetic foot ulcer: a single-blinded randomized controlled clinical trial. *Diabetes Res Clin Pract* 2014;106:548-54.
78. Ubbink DT, Vermeulen H. Spinal cord stimulation for critical leg ischemia: a review of effectiveness and optimal patient selection. *J Pain Symptom Manage* 2006;31:Suppl:S30-S35.

Copyright © 2017 Massachusetts Medical Society.

IMAGES IN CLINICAL MEDICINE

The *Journal* welcomes consideration of new submissions for Images in Clinical Medicine. Instructions for authors and procedures for submissions can be found on the *Journal's* website at NEJM.org. At the discretion of the editor, images that are accepted for publication may appear in the print version of the *Journal*, the electronic version, or both.