



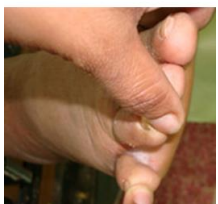

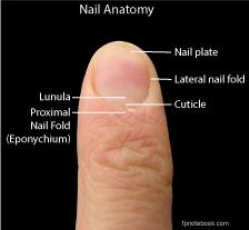





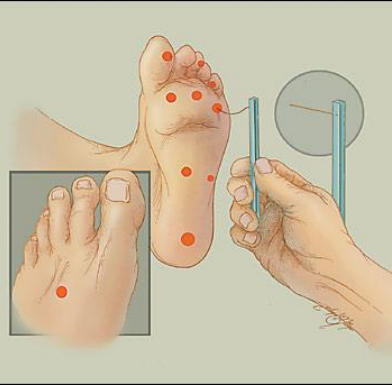
Careful inspection of the feet of our patients with diabetes on a regular basis is one of the easiest, least expensive and most effective measures for preventing foot complications and limb loss. Appropriate care of diabetic feet requires recognition of the most common risk factors which can be identified based on this brief but systematic examination in the office or clinic setting.

Question	Photograph	Examination Method	Significance of Yes Answers
1. Previous Ulcer		<p>Ask the patient</p> <p>Assess both lower legs and feet (dorsal and plantar surfaces) for the presence of a healed ulcer as evidenced by scar tissue</p>	<p>HIGH RISK for further DFU/Amputation</p> <p>Vascular impairment</p> <p>Sensory, Motor neuropathy</p> <p>Trauma/ Ill-fitting shoes</p> <p>Charcot foot</p>
2. Previous Amputation		<p>Count toes</p> <p>Observe if foot or limb amputation present</p>	<p>HIGH RISK for further Amputation</p> <p>Vascular impairment</p> <p>Sensory neuropathy</p> <p>Motor neuropathy</p>
3. Deformity		<p>Observe for deformity and/or abnormality in shape or structure of either foot</p>	<p>Risk for Charcot foot</p> <p>Loss of medial arch (intrinsic minus foot)</p> <p>High medial arch</p> <p>Motor neuropathy</p> <p>High pressure on bony prominences</p>
4. Absent Pedal Pulses		<p>Palpate Dorsalis Pedis & Posterior Tibial</p> <p>Note: Yes requires absence of both pulses</p>	<p>HIGH RISK for Ischemia</p> <p>Absence of Posterior Tibial is always an abnormal finding</p> <p>Vascular testing is recommended</p>

Check **all** web spaces for moisture/fungal infection



Question	Photograph	Examination Method	Significance of Yes Answers
<p>5. Active Ulcer</p> <div style="border: 1px solid blue; padding: 5px; width: fit-content;"> <p>Check footwear for wear patterns, items within shoe, suitability of shoe</p> </div>		<p>Assess both lower legs and feet (dorsal and plantar surfaces) for openings in the skin with a dermal or deeper base</p>	<p>HIGH RISK for further DFU/Amputation Infection/osteomyelitis Vascular impairment Sensory, Motor neuropathy Trauma/ Ill-fitting shoes Charcot foot</p>
<p>6. Ingrown Toenail(s)</p>		<p>Inspect distal corners of all nails for embedded nail and /or thickened skin at nail fold</p> 	<p>HIGH risk for infection</p>
<p>7. Calluses</p>		<p>Assess and inspect for presence of thick areas of keratin on the dorsum and sides of feet and toes on both feet</p>	<p>Sensory neuropathy Ulcer below callus Foot deformity High plantar pressures Ill-fitting shoes</p>
<p>8. Blisters</p>		<p>Inspect feet for fluid (serum, blood or pus) under intact skin surface</p>	<p>Sensory neuropathy Foot deformity Trauma High plantar pressures Ill-fitting shoes</p>

Question	Photograph	Examination Method	Significance of Yes Answers
9. Fissure (linear crack, dry skin)		Inspect feet for dry skin and linear cracks break with dermal base or deeper base	Autonomic neuropathy Loss of sympathetic innervation Infection Microvascular gangrene (poor healing) Aching, pulsation, tightness, cramping, pruritus
10. Monofilament examination		<p>Each foot is examined separately Use 10g Semmes Weinstein monofilament per schematic to left</p> <p>Record negative reaction a) Right _____/10 negatives (4 negatives = Yes) b) Left _____/10 negatives (4 negatives = Yes)</p>	<p>Large fibre neuropathy: Loss of protective sensation is associated with a seven-fold increase in risk of DFU</p> <p>Small fibre neuropathy Significant morbidity from stabbing/ burning pain, or abnormal sensation of the skin (tingling, cold or itchiness) Allodynia: numbness and exquisite sensitivity, pain often worse at night</p>

Testing for Sensory Neuropathy with 10g Monofilament

- Explain reason for testing sensation
- Demonstrate monofilament to patient’s arm or upper leg bending it in a letter “C” shape
- **ASK THE PATIENT TO CLOSE THEIR EYES**
- Push the monofilament until it bends, then hold for 1 to 3 seconds.
- Lift the monofilament from the skin. Do not brush or slide along the skin
- Randomly test all 10 areas on diagram (Do not test over calluses, scars or ulcers)
- **DO NOT ASK THE PATIENT** “did you feel that?” If the patient does not say ‘yes’ when you touch a given testing site, continue on to another site. When you have completed the sequence, RETEST the area(s) where the client did not feel monofilament.
- Record tested areas on foot images
- Lack of feeling (4 or more out of 10) - indicates a negative reaction = Neuropathy = “YES” on screening tool

Monofilament Testing Recording Sheet

